

Case Report

A 45-year X-ray observation report of mandibular alveolar bone density at an 81-year-old female patient whose alveolar bone density thickened greatly as a windfall beneficial consequence after her osteoporosis was treated with anti-RANKL monoclonal antibody following a 2009 tibia fracture

Harumi Kuno-Sakai, MD, PhD¹⁾, Hidefumi Marumori²⁾, Mutsuo Fukushima³⁾, Hiroyuki Sakai, MD, PhD⁴⁾, Takeshi Miyamoto, MD, PhD⁵⁾, Taito Itabashi, MD, PhD⁶⁾, Hideto Sakai, MD, PhD⁷⁾

(Translation completed on Sept. 4, 2021)

¹ Director, Geriatric Health Services Facility Towada run by Social Welfare Corporation Miyagikai in the SG Group, Regular member of the Japanese Society of Clinical Virology. Journalist, former staff reporter at the World Services Section of Kyodo News' International Department

² Marumori Dental Clinic, 6-68-1 Yokohama Kannai Zisho Building 9F. Sumiyoshi-cho, Naka-ku, Yokohama city, Kanagawa, 231-0013 Japan

³ Regular member of the Japanese Society of Clinical Virology. Journalist, former staff reporter at the World Services Section of Kyodo News' International Department

⁴ Sakai Clinic, 9-34 Imaiminami-cho, Nakahara-ku, Kawasaki city, Kanagawa 211-0064 Japan

⁵ Formerly Associate Professor, Department of Orthopedics, Medical School Keio University, Professor, Department of Orthopedics, Medical School Kumamoto University, Honjyo 1-1-1 Chuo-ku, Kumamoto city, 860-0811 Japan

⁶ Associate Professor, Hirosaki University, Director Division of Orthopedics, Towada City Hospital, 14-8 West No.12 Towada city, Aomori Prefecture, 034-0093, Japan

⁷ Director, Geriatric Health Services Facility Shimoda run by Jinsenkai, a medical corporation run by the SG Group of nursing-care facilities for the elderly.

Corresponding author:

Harumi Kuno-Sakai, MD, Director, Geriatric Health Services Facility Towada, run by Miyagikai, a social welfare corporation of the SG Group of nursing-care facilities for the elderly, Towada City, Aomori 034-0107, former professor at Tokai University School of

Medicine's Department of Public Health and Pediatrics, Isehara City, Kanagawa Prefecture, Japan. Former President of the Japanese Society of Clinical Virology

Japan Tel: +81- 176-27-3131

e mail address: clin.viol@nifty.com

Key words: Osteoporosis, Mandibular trabeculation, Alveolar bone, Bone Mineral Density, Dual-Energy X-Ray Absorptiometry, Anti-RANKL monoclonal antibody

ABSTRACT

Objective: A digestive tract is the most important organ system for the well-being of animals, including humans. A digestive tract starts stretching from an animal's oral cavity. At the entrance of a human oral cavity are located two opposing arches of teeth, which are called the maxillary arch and the mandibular arch. The root of each tooth on the upper and lower arches respectively fits into the maxilla and mandible.

This medical dissertation revolves around a windfall improvement of the mandibular alveolar bone density at an 81-year-old female whose osteoporosis has been treated with a mix of the most advanced medicines, including a monoclonal antibody against the Receptor Activator of Nuclear Factor Kappa B Ligand (RANKL), after she sustained fractures of her left tibia and fibula at a skiing accident on January 26, 2009.

Surgeons at the Towada City Hospital in Aomori Prefecture counteracted the tibia fracture by inserting a cylindrical titanium alloy rod into the medullary cavity of her tibia shaft. After the patient, herself an internal medicine doctor, detected clear signs of a progressing osteoporosis in March 2010 in examining X-ray images of her left tibia and fibula, however, she asked for medicine-based osteoporosis treatment to prevent her osteoporosis from inflicting any further serious damage to various parts of her skeletal structure.

Of the five types of medicines that have been since administered to the patient orally or through injections during the subsequent 11-year treatment period, the anti-RANKL monoclonal antibody, which has been injected at a frequency of once in every six months from January 2015, proved most efficacious in blocking any further progression in her osteoporosis and even turning around falling bone mineral density (BMD) readings throughout her skeletal structure with the anti-RANKL antibody restraining and curbing the activity of osteoclasts, a large multinucleated cell, possibly of monocytic origin, which functions in the absorption and removal of osseous tissue.

The monoclonal antibody even produced a windfall beneficial consequence for her mandibular alveolar bone by bolstering the density of the bone, which

provides a solid foundation for humans' overall dental health and thus for their overall bodily health. This finding, whose details are reported in this paper, may prove to be an excellent news for odontology researchers and dentists who are interested in solidifying and strengthening the supporting structure at their patients' mandible and maxilla.

Luckily for such researchers and dentists, the density of the patient's mandible alveolar bones, a chief subject of the windfall beneficial improvement, has been observed for as long as 45 years with an X-ray apparatus at a dental clinic, in Yokohama, Kanagawa Prefecture, starting on April 9, 1976. Starting in the year when she was 36 years old, the patient has been examined and treated by dentists at the Marumori Dental Clinic in the historic port city west of Tokyo.

She has undergone periodic dental checkups as well as treatments of decayed teeth, whenever necessary. Initially, she used to receive medical treatments from Dr. Kenji Marumori (1921-2002), the founding director of the clinic, until the clinic's directorship was handed over to Dr. Hidefumi Marumori, a son of the director. Dr. Kenji Marumori used to follow a key tenet of refraining from extracting his patients' natural teeth as far as possible. His son has been following the sound tenet.

During the latest 11-year portion of the 45-year intra-oral X-ray observation period at the dental clinic, the 81-year-old patient has been getting doctors at two other hospitals – the Keio University Hospital in Tokyo and the Towada City Hospital -- to examine and treat her osteoporosis with the use of multiple medications, including an eldecacidol, a bisphosphonate, a teriparatid and the anti-RANKL monoclonal antibody. (Table 1)

She has visited the Yokohama dental clinic once in every four to six months for more than four decades. Some years after the medicines-based osteoporosis treatment got under way, the patient noticed that there is a significant and wondrous correlation between a conspicuous improvement in the fineness and minuteness of her left mandibular spongy bone's latticelike structure -- which she then assessed with her own four-grade density-rating method that involves examining her left and right mandibles' X-ray images visually -- and a striking improvement in bone mineral density readings at her lumbar vertebrae (L2-L4)

as well as at the necks and proximal parts of her right and left femurs, which have been measured with the Dual-Energy X-ray Absorptiometry (DEXA) machines at the Keio University Hospital and the Towada City Hospital, each time she got these parts to be examined and scanned with the DEXA machines to check the degrees of the severity of her osteoporosis.

She assigned one of four ratings ranging from B to A triple stars (in other words, an A+++, or A triple-plus) to X-ray images of her left and right mandibles. The method involves visually examining a mandible's X-ray images and then verifying the appropriateness of the ratings she assigned to each X-ray image, while referring to BMD readings and unique BMD indicators that were measured and computed by a digital multi-slice bone densitometer of General Electric Co. subsidiaries.

Periodic measurements of BMD readings at the patient's skeletal parts began on November 2, 2012 – three years after she sustained fractures at her left tibia and fibula at the skiing accident on the slope of Mt. Yakeyama near a large caldera lake in Aomori Prefecture.

The most important finding of this dissertation is that the intra-oral X-ray images corroborated the fact that the bone density at her mandibular alveolar bone's trabecular segments has become greater over the past eight years as a windfall beneficial consequence of medicine-based osteoporotic treatment which has been given to her during the same period. Of the multiple medicines administered to her, the anti-RANKL monoclonal antibody has acted as the most effective factor that has induced a dive in the degree of the severity of her osteoporosis.

What is noteworthy is that this striking reduction in the degree of the severity of her osteoporosis has been confirmed by generally continual increases in the patient's BMD readings since January 2015 at the lumbar vertebrae (L2~4) and the necks and proximal parts of her right and left femurs.

The speed with which the patient's BDM readings rebounded after they underwent many years of osteoporosis-induced BMD declines accelerated after

Keio University Hospital began administering on January 16, 2015 the anti-RANKL monoclonal antibody to the patient with periodic syringe-based injections.

Prior to that point, her BMD readings had been recovering, only slowly, thanks to daily teriparatide injections which the patient administered to herself, starting on December 25, 2012, in accordance with a prescription written out for her by the same hospital until she discontinued the injections in August 2014 as directed by the hospital in preparation for the start of the monoclonal antibody's injections.

Backed by the close visual examination of the X-ray images of the right and left parts of her mandible -- whose findings are in agreement with the improvements in her BMD readings that mirror a clear reduction in the degree of the severity of her osteoporosis since 2013 and with improvements in BMD-related indicators -- we conclude that the bone mineral density of the alveolar bone's trabecular segment at her right mandible has thickened to a high level almost equivalent to the same segment's density when she was 39 years old, while that of the alveolar bone's trabecular segment at her left mandible thickened to reach an even higher level almost equivalent to a density which the same segment had when she was 36 years old.

We present in this paper (1) the intra-oral X-ray images of the patient's mandible which have been kept at the Marumori Dental Clinic since 1976 (2) the X-ray images of the same patient's chest taken at a medical clinic in Kawasaki City, Kanagawa Prefecture, which has been run by her son, also an internal medicine specialist. The chest radiographs, taken in 2007 and 2020, attest to increases in the bone mineral density at both her clavicle and cervical vertebrae after her osteoporosis was treated with multiple medicines including the anti-RANKL monoclonal antibody (3) a series of X-ray images of the patient's left tibia and fibula, taken postoperatively after she sustained their fractures at the 2009 accident and (4) a string of BMD readings at her lumbar vertebrae (L2-L4) as well as at her femurs since November 2, 2012.

We examined bone density-related changes in numerous X-ray images of the patient's mandible since 1976, those in the X-ray images of her cervical vertebrae and clavicles since 2007, as well as those in radiographs of the

patient's left tibia and fibula since 2009, while checking ups and downs in BMD readings measured with the DEXA machines since November 2, 2012.

The DEXA measuring instruments of the General Electric Co. Group like Lunar iDXA use a special indicator that denotes the bone mineral density of skeletal parts in terms of a unit of g/cm^2 . We also examined T-score readings computed by the DEXA measuring instruments. A T-score represents how far an examinee's BMD reading has deviated from the mean of BMD readings for young adults of the same sex during a certain span of time. Table 2 provides a more detailed explanation on how a T-score is computed.

The density of mandibular alveolar bone in a series of X-ray images was assessed on the basis of a close visual examination of the X-ray images. In order to make results of these visual comparisons as accurate as possible, we chose and adopted our own reference images in a manner similar to the comparison method proposed by Lindh et al. and modified by Jonassen et al. Please see "Reference Images adopted by Authors to Evaluate Subtle Changes in the Mineral Density of Alveolar Trabecular Bones" to check our own reference images. (Figure 4) Subtle changes in the degrees of a light and shade in the patient's mandibular trabecular bones' X-ray images were evaluated by performing visual comparisons with these reference images.

We believe that it is scientifically appropriate to perform a credible assessment of changes in the bone mineral density of a mandibular alveolar bone on the basis of a close visual examination of a long temporal series of X-ray images of the mandibular bone. We have concluded that medication-based treatments of osteoporosis administered to the patient has produced a brilliant upsurge in the bone mineral density of her mandibular alveolar bone. All of BMD, T-score and Z-score readings collected with the DEXA, particularly during the past six years and seven months, indicate that the anti-RANKL monoclonal antibody is largely responsible for improvements in the density of mandibular alveolar bone and many other parts of the patient's skeleton.

Table 1. List of medicines prescribed for the case reported in this article

Chemical name	Brand name	Comments
Alfacalcidol. 1-Hydroxycholecalciferol. 1alpha-Hydroxyvitamin D3.	Alpharol cap 1µg	This hepatically-metabolized medicine turns into activated vitamin D3 and facilitates digestive tracts' absorption of calcium.
Eldecalcitol, Vitamin D3	Edirol cap 0.75µg	Launch date: April 8, 2011. Eldecalcitol hikes bone mineral density, strengthening bones and making osteoporosis-induced fractures less likely.
4-Amino-1-Hydroxybutylidene 1,1-Bisphosphonate	Benet (Sodium risedronate hydrate) 17.5mg	Bisphosphonates are used to both prevent and treat osteoporosis at postmenopausal women. It helps inhibit osteoclasts' activity, slowing bone density cutbacks and lowering the risk of spinal and hip fractures.
Teriparatide	Forteo for subcutaneous injection 600µg	Human parathormone's 34-amino-acid N-terminal (recombinant). A human-derived parathormone must be administered intermittently. By this manipulation, osteoblasts can be activated. This medicine is useful for osteoporosis treatment.
Monoclonal antibody against RANKL	Denosumab Prolia, sold under PRALIA brand in Japan (Genetically recombined drug)	Japan approved this drug's manufacturing and sales on March 25, 2013. PROLIA® is a fully human-derived monoclonal antibody that specifically inhibits RANKL*, an essential mediator for bone resorption. It is given via a subcutaneous injection for use once in every six months. Warnings: Patients need to receive regular Prolia injections on a life-long basis, since a rebound in the activity of osteoclasts would occur if a six-month-interval injection were interrupted or discontinued.

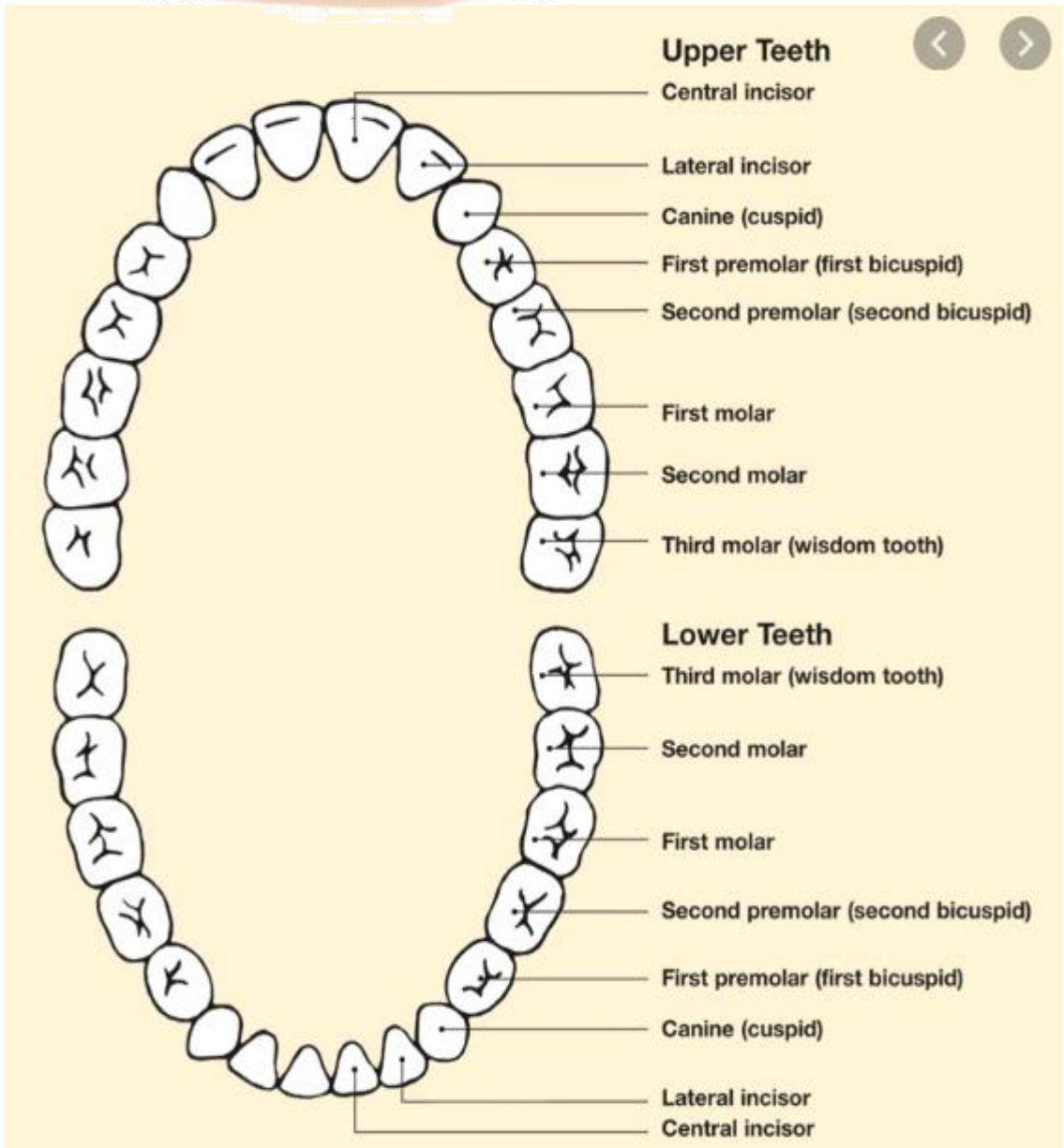
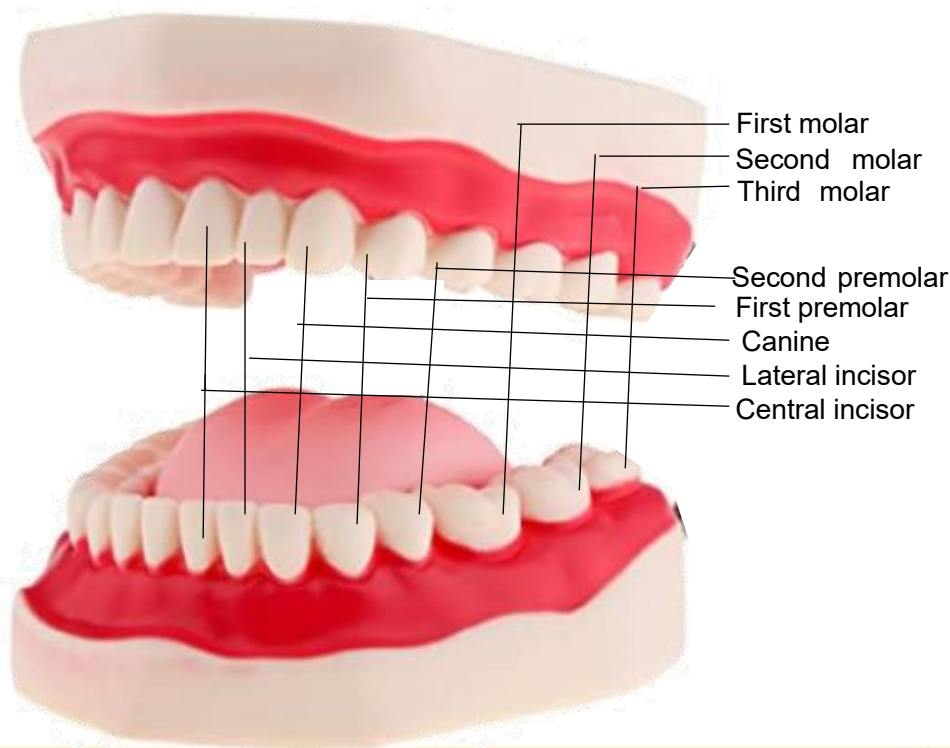
Table 2. Technical terms with explanations

Alveolar bone	The alveolar process (also called the alveolar bone) is the thickened ridge of bone that contains the tooth sockets (dental alveoli) on the jaw bones that hold teeth. In humans, the tooth-bearing bones are the maxilla and the mandible. The curved part of each alveolar process on the jaw is called the alveolar arch.
Osteoporosis	<i>Osteoporosis</i> literally means porous bone. It is a disease in which the density and quality of bone are reduced. As bones become more porous and fragile, the risk of a fracture increases greatly.
Bone mineral density (BMD)	Bone mineral density (BMD), a measure of bone density, mirrors the strength of bones as represented by calcium content. A BMD test detects osteopenia (mild bone loss, usually without symptoms) and osteoporosis (more severe bone loss, which may cause symptoms).
Young Adult Mean (YAM)	Young Adult Mean (YAM), a statistical value referred to in this paper, is the mean bone mineral density at Japanese young adults. YAM is the basic value used to diagnose whether a patient should be classified as being in the category of osteoporosis or that of osteopenia, or neither. Under the diagnostic criteria for Japanese females issued in 2012, the lumbar vertebrae YAM was computed by using data collected from a cohort of females aged between 20 and 44, while the YAM for proximal femur was computed by using data collected from a cohort of females aged between 20 and 29.
Normal bone density	Normal bone density signifies BMD readings that show up in a zone within 1 standard deviation (SD +1 or -1) from the YAM.
Low bone density (Osteopenia)	BMD readings of osteopenia-affected persons are between -1 and -2.5 SDs below the YAM (-1 to -2.5 SD). Comments: Postmenopausal women whose T-scores fell to less than -1.0 SD are defined as those affected by a low bone density. They are at greater risk of developing osteoporosis. Although risk of sustaining a fracture is lower at this group than among females with osteoporosis, >50% of fractures among postmenopausal women, including hip fractures, occur in this osteopenia group.
DEXA (Dual-energy x-ray absorptiometry).	DEXA is short for Dual-energy X-ray Absorptiometry. It is a technique for scanning bone and measuring BMD. A DEXA scanner is a large machine that beams X-ray beams of two different energies. One beam carries higher energy, while the other bears lower energy. The quantity

	<p>of x-rays that pass through a bone site is measured for each beam. Resultant energy readings vary depending on the thickness of a bone. By examining a difference in energy levels between the 2 beams that successfully passed through a bone site, the site's BMD can be measured. A DEXA scan is relatively easy to perform and the quantity of radiation to which an examinee is exposed can be limited.</p>
T-score (DEXA score)	<p>A T-score value is computed through a comparison of a patient's BMD with the YAM density at persons of the same sex. A T-score of -2.5 or lower indicates that the examined has osteoporosis. The greater the absolute value of a negative number, the more severe the examinee's osteoporosis.</p> $\text{T-score} = \frac{\text{Patient's bone density} - \text{young adult mean}}{\text{Standard Deviation (SD)}}$ <p>A T-score shows how greatly an examinee's bone density has deviated from the YAM. T-score values of -1.0 or above mean that holders of the values carry a normal bone density. But a T-score value between -1.0 and -2.5 indicate that a bone density at holders of such scores is low and that the examinee has osteopenia.</p>

First of all, let us call readers' attention to medical terms assigned to each of a human's teeth embedded on the mandible and maxilla with Figure 1, and then to those assigned to structural constituents of a human's tooth with Figure 2 (a) and (b).

Figure 1. Names of teeth



PREFACE

Structure of Tooth and Gingiva

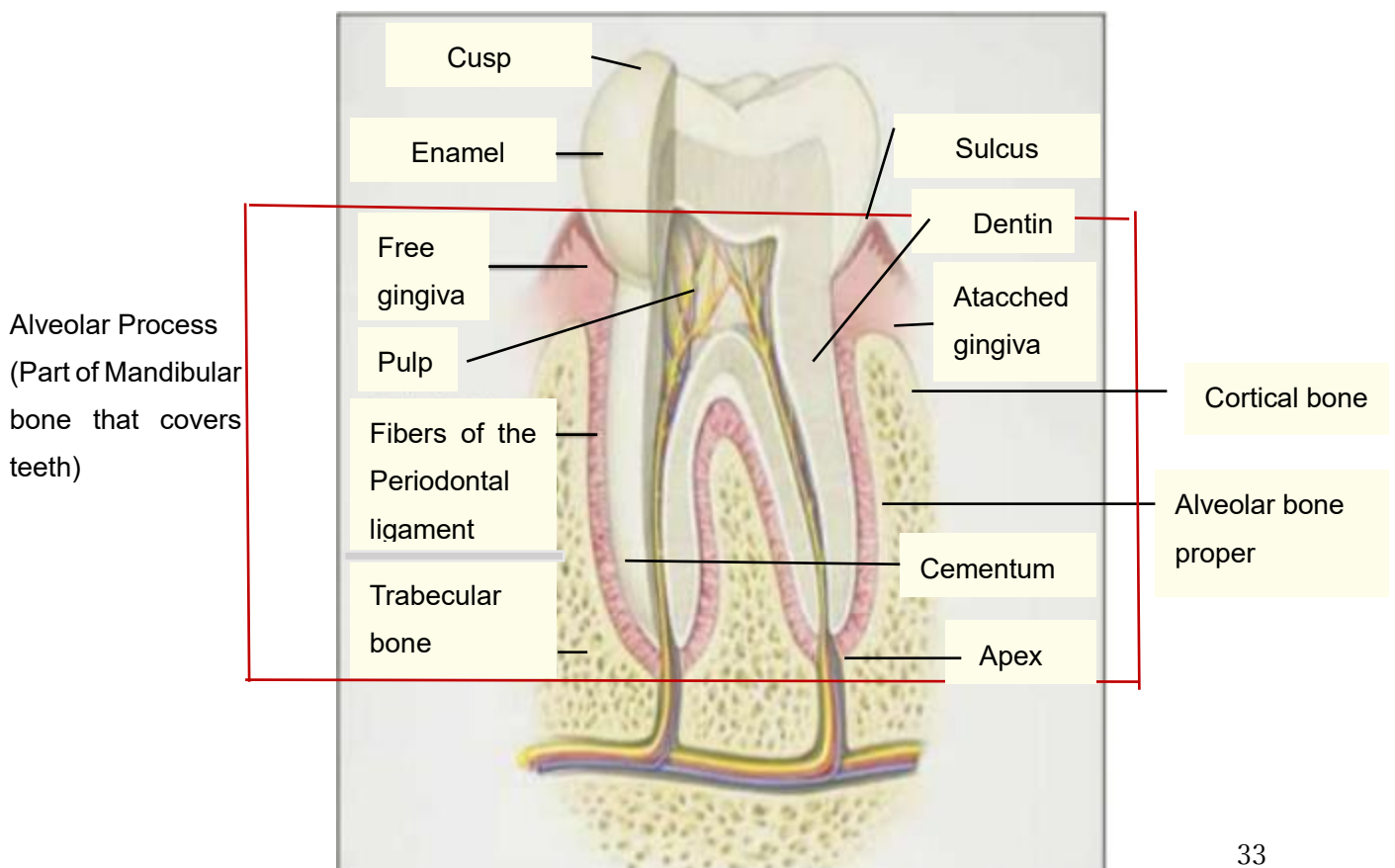
Adult humans usually have 32 permanent teeth, including four third molars. Each tooth has a name. Incisors and canines respectively have shapes suitable for cutting and tearing foods. Molars and premolars' shapes are suitable for crushing foods. A tooth can be divided into two main parts – the crown and the root. The part of a tooth which is visible in the mouth is referred to as the crown, while the part which is not visible is the root. The crown is covered by enamel. Enamel is a robust, avascular hard tissue with a high mineral content like calcium phosphate and is the hardest among all tissues of a human body. A layer of dentin, a vital tissue that accounts for the majority of the hard tooth structure, lies beneath the enamel and cementum. Cementum is a specialized bone-like substance covering the root of a tooth. The principal role of cementum is to serve as a medium by which the periodontal ligaments can attach to the tooth for stability. The dental pulp is the central part of the tooth filled with soft connective tissue. This tissue contains blood vessels and nerves that enter the tooth from a hole at the apex of the root. Along the border between the dentin and the pulp are odontoblasts, which initiate the formation of dentin. Other cells in the pulp include fibroblasts, preodontoblasts, macrophages and T lymphocytes.

Structure and Function of Periodium.

The periodontium is the supporting structure of a tooth, helping to attach the tooth to surrounding tissues and to allow sensations of touch and pressure. It consists of gingiva, alveolar bone, the periodontal ligaments, and cementum. Gingiva is the mucous tissue which overlays the upper and lower jaws. The periodontal ligament is a specialized connective tissue that attaches the cementum of a tooth to the alveolar bone. This tissue covers the root of the tooth within the alveolar bone. When pressure is exerted on a tooth, such as chewing and biting, the tooth moves slightly in its socket and puts tension on the periodontal ligaments. The nerve fibers can then send the information to the central nerve system for interpretation. Alveolar bone: The alveolar bone is the bone of the jaw which forms the alveolus around teeth. Osteoblasts create the bone and osteoclasts destroy it like any other bone in the human body. It consists of two components with the first being the alveolar process and the

second the alveolar bone proper, which is the portion of bone that lines the tooth socket. The alveolar process consists of two layers with the outer layer being of cortical bone and the inner region of cancellous bone. The cortical bone is similar to that seen in other regions of the skeleton, comprising lamellar bones. It carries the Haversian systems for bone maintenance and remodeling.

Figure 2(a). Structure of a tooth



Trabeculae: Inside the alveolar bone, which forms the alveolus or the “socket” for a tooth, there is a meshwork of small pieces of the spongy substance of bone which are interconnected with other similar pieces. Trabeculae bones found in the supporting structure of teeth play the same role as those found in femurs and vertebrae.

Sulcus: The sulcus often acts as the portal of entry for oral bacteria which cause periodontitis, a kind of inflammation. An advanced periodontal disease induces the loss of periodontal ligaments, while destroying the alveolar bone. For many years, inadequate levels of attention have been paid to adverse changes in alveolar bone and periodontal ligaments that occurs as humans grow old. It has been said that damages to an alveolar bone occur mostly as a result of a periodontitis. Recently, however, dentists and researchers of odontology have come to pay greater attention to dental damages that take place as humans grow old. ¹⁾ Moutsopoulos

Figure 2(b). Structure of a tooth

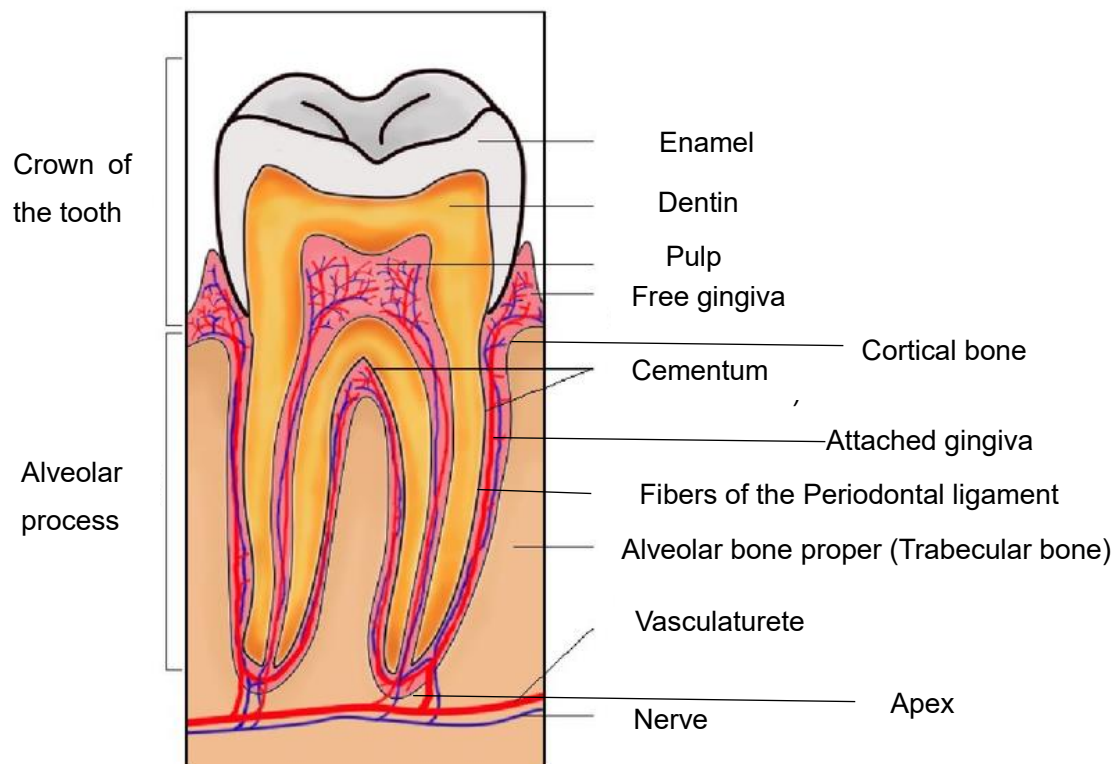
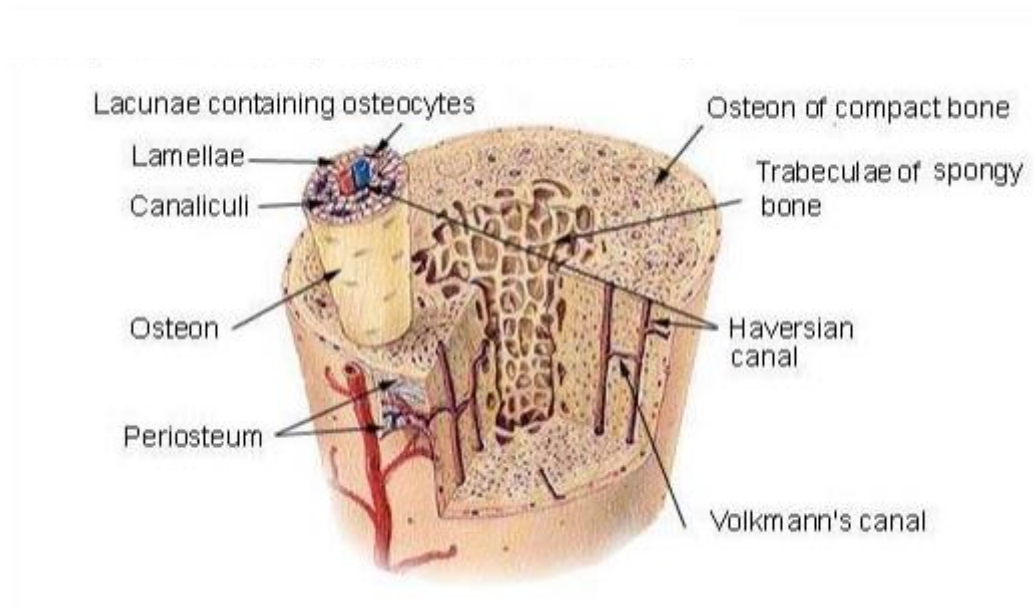


Figure 3. Compact Bone and Spongy Bone (Cancellous bone)

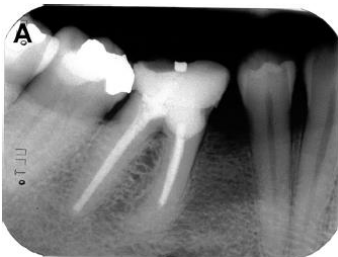

Reference images

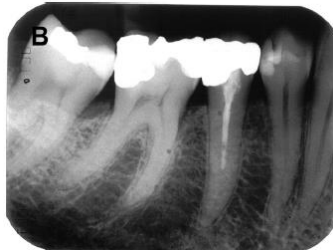
Figures 4 and 5 respectively show a set of reference X-ray images proposed by Lindh et al. and modified by Jonassen et al. for the comparative evaluation of the degree of the severity of osteoporosis of teeth, as well as those adopted by authors to conduct an objective comparison of X-ray images discussed in this article.

Figure 4. Reference images proposed by Lindh et al. and modified by Jonasson et al. ¹⁾

A. dense trabeculation with trabeculation with small intertrabecular spaces cervically and larger spaces



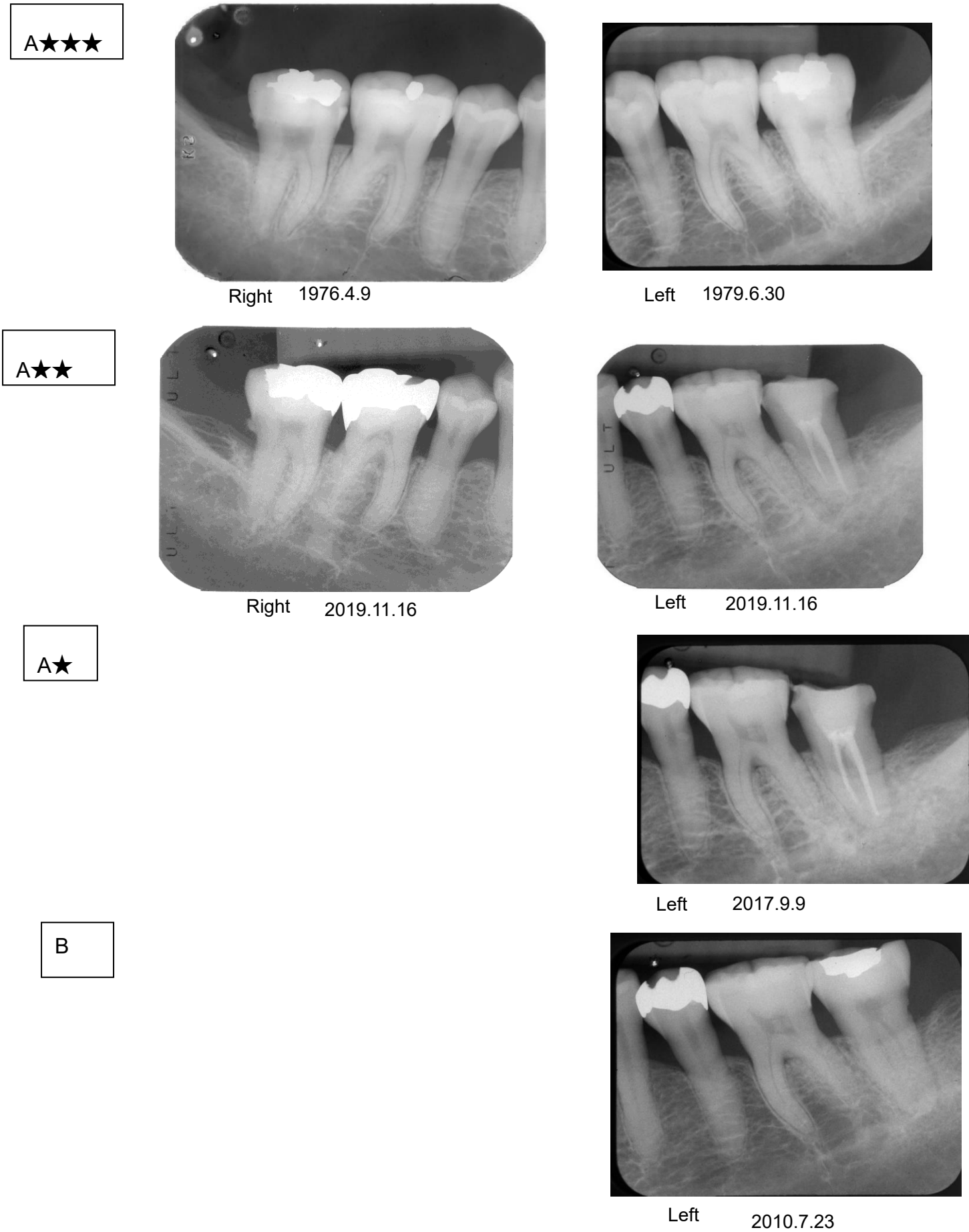
B. mixed dense and sparse small intertrabecular spaces cervically and larger spaces apically



C. sparse trabeculation with larger intertrabecular spaces and almost invisible trabeculae

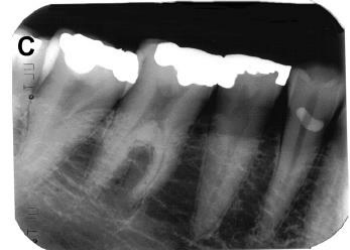

Figure 5. Reference Images adopted by Authors to Evaluate Subtle Changes in the Mineral Density of Alveolar Trabecular Bones



PATIENT AND METHODS

Family of the Patient: Dr. Toru Kuno, grandfather of the patient, was born in Fukui Prefecture in April, 1894. In 1922, he passed the national examination to receive a state certification as a professional dentist, the first for the profession organized by the Japanese national government. He was state-certified as such on June 29, 1922. Figure 6 (a) shows his pass certificate. He opened a dental clinic at Maizuru City, Kyoto Prefecture. However, on December 8, 1941, the United States formally entered World War II in the aftermath of the Imperial Japanese Navy Air Force's surprise attack on Pearl Harbor in Honolulu, Hawaii. Since Maizuru was then home to one of Japan's four biggest naval installations, her grandfather developed angst that Maizuru may be attacked by the U.S. Air Force sooner or later. This angst proved well-founded in July 1945, when U.S. Air Force bombers assaulted the port city.

In 1942, her grandfather moved out of the city to reside in Kosugi, Kawasaki City, Kanagawa Prefecture, which was not very far from the location of the residence of his daughter, who is the mother of the patient. He then opened a dental clinic on June 15 1942. The clinic was located in front of the Musashi-Kosugi Station of the Tokyu Toyoko Line. At present, St. Marianna University School of Medicine's Toyoko Hospital is at the exact location where his dental clinic was present. The patient remembers that three doctors used to work at the dental clinic in the years that followed Japan's surrender to the Allied Powers led by the United States in 1945.

Figure6 (a)

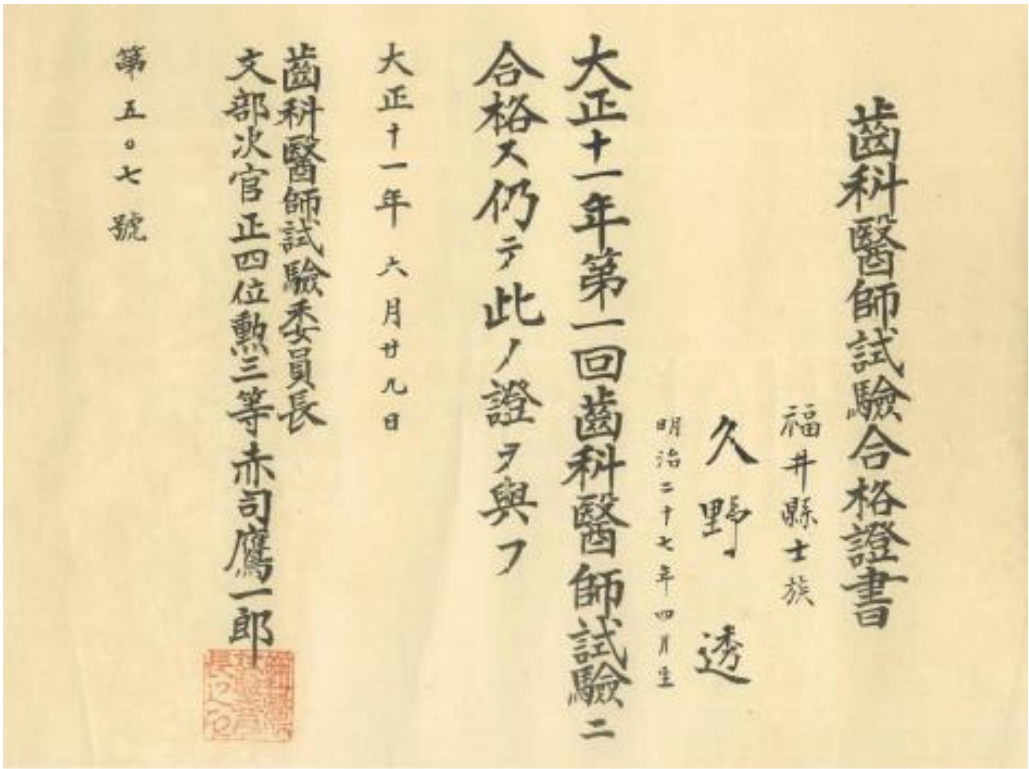
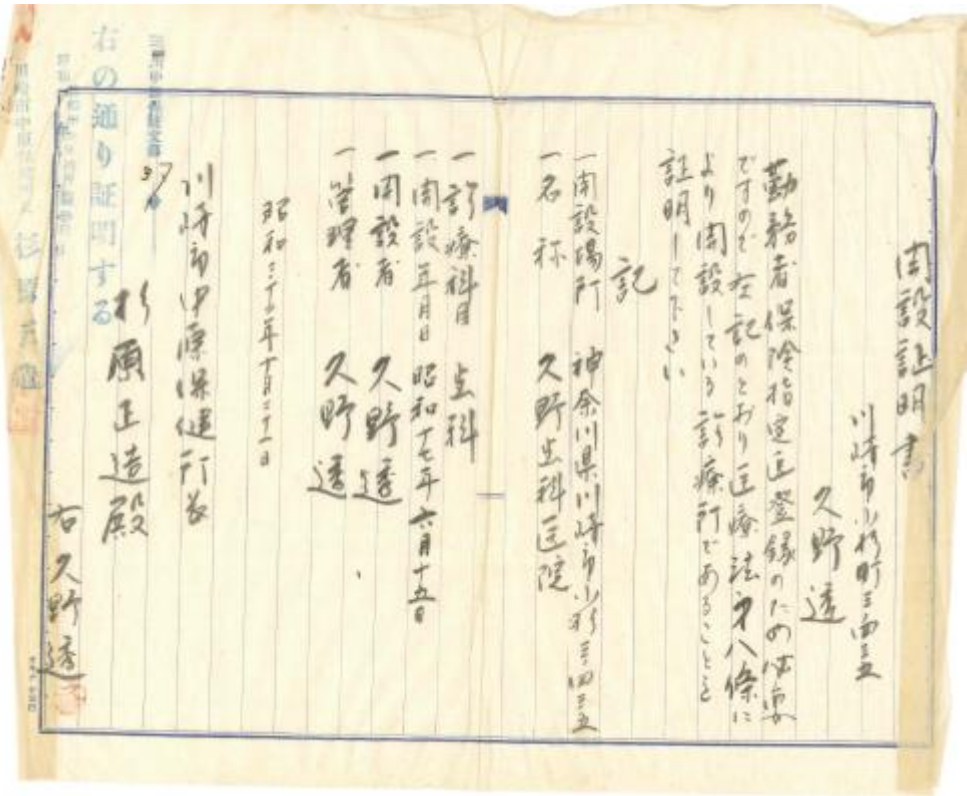


Figure 6 (b)



Patient: The patient was born on January 17, 1940. She did not develop any dental problem until she entered her early teens. However, she started to suffer from a dental caries after she entered a junior high school. She used to get her decayed teeth to be treated at her grandfather's dental clinic occasionally. Besides this, she had to have her wisdom teeth extracted.

After graduating from Keio University, School of Medicine, and getting married, the patient moved with her husband in 1969 at the age of 28 to the United States, where she started to work as a researcher at the University of Texas, Medical Branch, in Galveston. While she was staying at Galveston, she used to receive treatments at a local dental clinic named the Dr. Potts Clinic for a couple of times. Ever since she returned to Japan from the United States in 1975, she has been receiving periodic dental checkups, and treatments whenever necessary, at the Marumori Dental Clinic.

Method: On top of radiographical checks at the dental clinic, the patient has been getting two other hospitals – the Keio University Hospital and the Towada City Hospital -- to radiographically examine her skeletal parts as part of her osteoporotic treatment. The two hospitals have been measuring her BMD values with their high-definition multi-slice bone densitometers, although they use different DEXA models manufactured by subsidiaries of General Electric Co. of the United States. The Keio University Hospital uses a Lunar Prodigy with the Towada City Hospital using a Prodigy. Both models analyze their measurement results with an automatic analytical software. The software of the two models have been adjusted to use different YAM values as a basis for calculations. All data in this report have been converted by the authors by adopting the YAM values used by the Towada City Hospital scanner as the sole calculation basis in order to ensure the accuracy of the comparison of measured results, such as BMD readings and T-scores, and our analysis of the data.

Figure 7. Direct Digital & Multi-Slice Bone Densitometer (Lunar iDXA)



Table 3. Comparison of the BMD Mean for Young Adult Females in terms of the unit (gram/cm²) used by Prodigy scanner at Towada City Hospital and the BDM YAM Mean used by the Lunar Prodigy scanner of GE Medical Systems, USA, at Keio University Hospital. Both GE scanners use Dual-Energy X-ray Absorptiometry. The difference is that Towada's criteria are consistent with JSBMR's 2012 norms, whereas Keio's are consistent with 2000 JSBMR norms.

Date of Patient's Visit to Out Patient Clinic	Hospital	System	Diagnostic criteria	Lumbar Vertebrae (Front) L2-L4	Proximal Femur (Total)	Femur Neck
2019/8/8	Towada City Hospital	Dual-energy X-ray absorptiometry (PRODIGY, GE Healthcare; Madison, Wisconsin, USA) Software version 13.15 compatible)	2012 Diagnostic criteria ¹⁾ (based on 1996 Guideline data ³⁾ (Capable of using Software Version 13.1)	YAM (young adult female age: 20~44 year) 1.192 g/cm²	YAM (young adult female age: 20~29 year) 0.961 g/cm²	YAM (young adult female age: 20~29 year) 0.939 g/cm²
2012/11/02~2021/7/16	Keio University Hospital	Another DEXA scanner: Lunar Prodigy; GE Medical Systems, Madison, Wisconsin, USA)	2000 Diagnosis criteria ⁴⁾ (based on 1996 Guideline ³⁾ Data)	YAM (young adult female age: 20~44 year) 1.12 g/cm²	YAM (young adult female age: 20~44 year) 0.934 g/cm²	YAM (young adult female age: 20~44 year) 0.9 g/cm²

RESULTS

Bone mineral density: Treatment for this patient's osteoporosis started in May 2010. **Figure 8** provides an illustration of the names of medicines prescribed to her and the names of hospitals which this patient visited since May 2010. (See the upper-left and upper-right parts of the figure)

Measurements of the bone mineral density of the patient's vertebrae, right and left femurs with the DEXA machines got under way at the Keio University Hospital in November 2012, when she was 72 years old. The measurements have been conducted every 6 months at the Keio University Hospital and/or at the Towada City Hospital until the present day (July 2021).

The lower half of Figure 8 shows temporal changes of her T-scores at the vertebrae L2-L4 as well as at the necks and proximal part of her femurs. It is crucial to note how her T-scores have been following a generally upward path over the past eight years after the start of the administration of the teriparatid and the anti-RANKL monoclonal antibody.

The patient injected the teriparatide to herself hypodermically on a daily basis from December 25, 2012 to mid-2014. Meanwhile, the anti-RANKL antibody was injected at a 6 months' interval by Keio University nurses. Among various skeletal parts, the scope of increase in the bone mineral density -- represented in terms of both BMD readings and T-scores -- were sharpest at her L2-L4 vertebrae. The scope of bone mineral density increases at the necks and proximal parts of her femurs were not as sharp as those at the L2-L4. As of January 15, 2021, her T scores at the L2-L4 and the necks of the right and left femurs remained in the zone lower than -3.0 standard deviations. This means that all of T-scores at the skeletal parts were lower than their mean for young adults (YAM) by more than -3.0 SDs. Whether a person's BMD has fallen by more than 2.5 SDs below the YAM is the criteria with which Japanese experts judge whether a person has an osteoporosis. Therefore, the patient is definitely diagnosed as an osteoporosis case.

Mandible: Figure 9 shows the right and left alignments of this patient's teeth. **Figure 10** shows changes in X-ray images of her right and left mandibles as years went by. The series of X-ray photos clearly show how effective the treatment of osteoporosis, especially with the anti-RANKL antibody, has been in bolstering her mandibular alveolar bone's mineral density.

Figure 8 (Left) This Patient's Drug Prescription History from May 2010 to October 2021

	2010	2011	2012	2013	2014
Alphacalcidol		2010/5/10			
Eldecacidol				2012/8/24	
Biphosphonate		2010/7/30			
Teriparatid				2012/12/25	
Monoclonal antibody against RANKL					
Hospital and Clinic		Towada City Hosp. Hachinohe City Hosp. Sakai Clinic		Keio Univ. Hosp. Sakai Clinic	

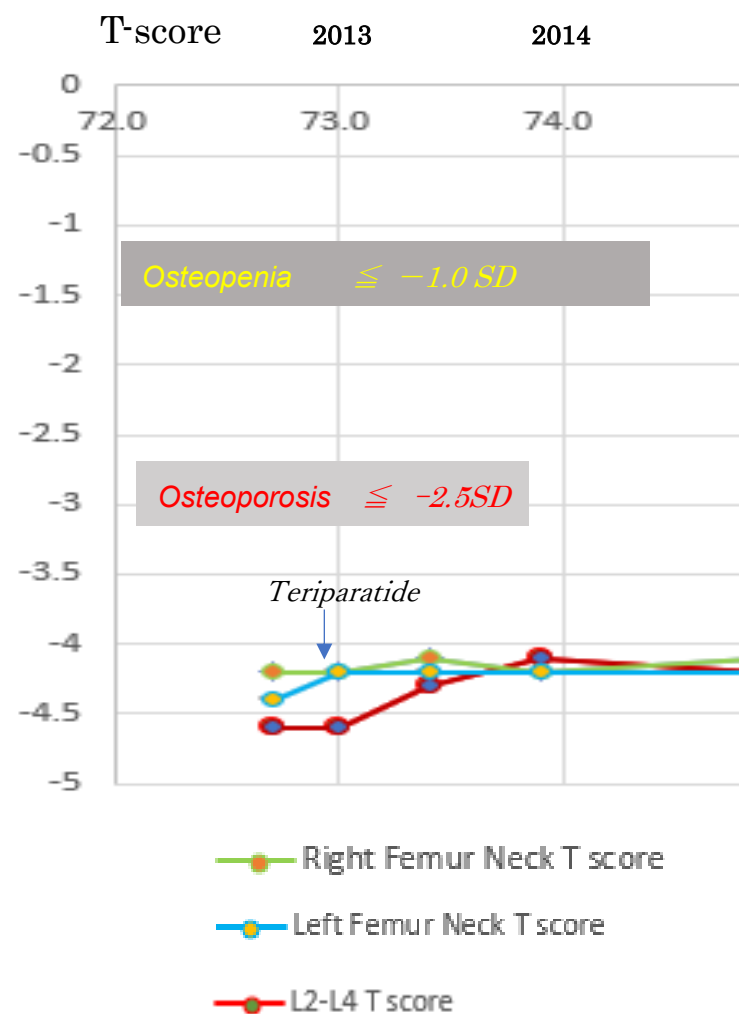
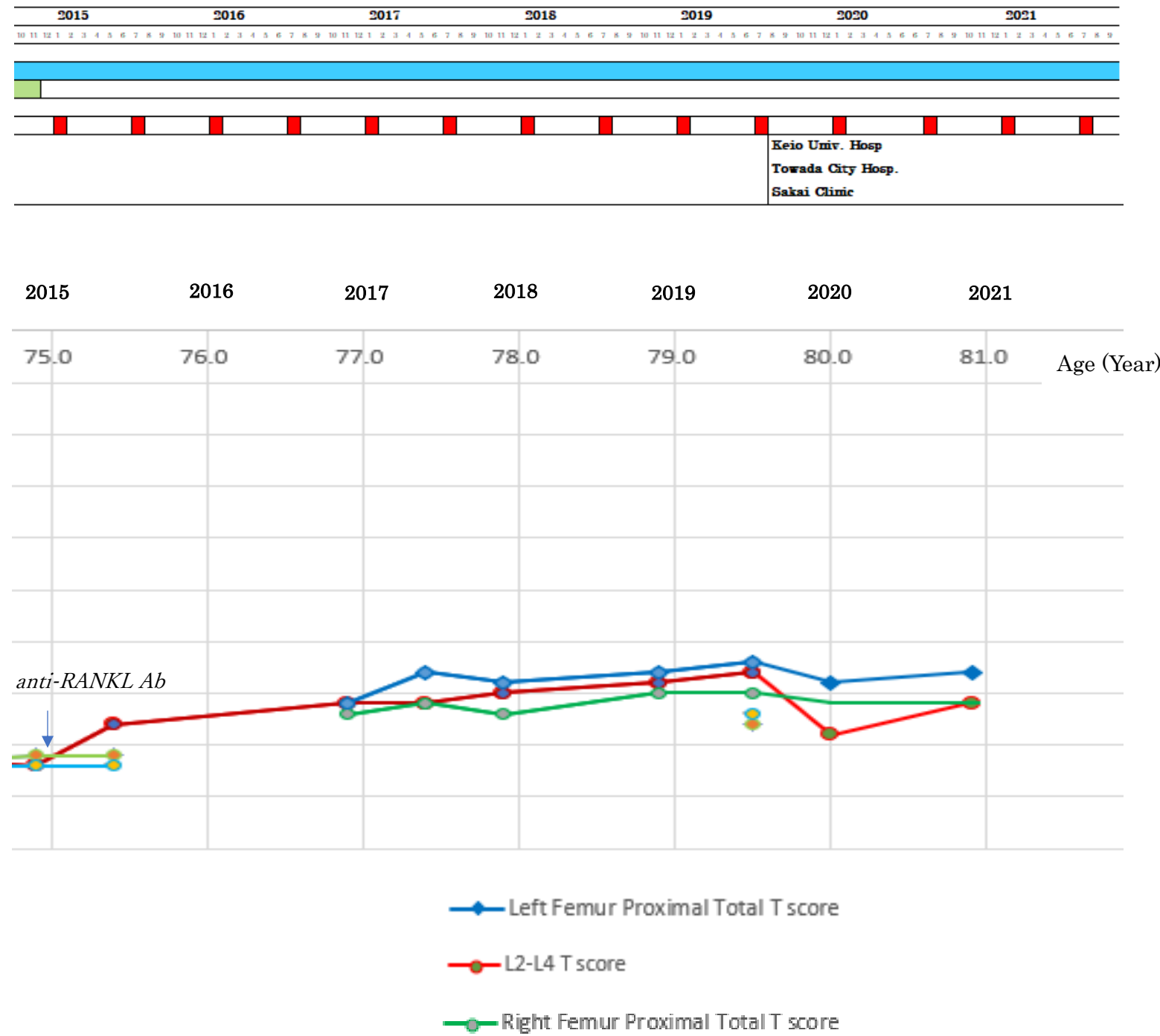


Figure 8 (Right) This patient’s Drug Prescription History from May 2010 to September 2021



Please see the appendix at Pages 44-46 for raw data of the patient’s recent bone mineral density (BMD) readings, the ratio of BMD to the YAM and her T-score, all measured on January 17, 2020, and January 15, 2021, at the Keio University Hospital.

Figure 9. Alignments of teeth

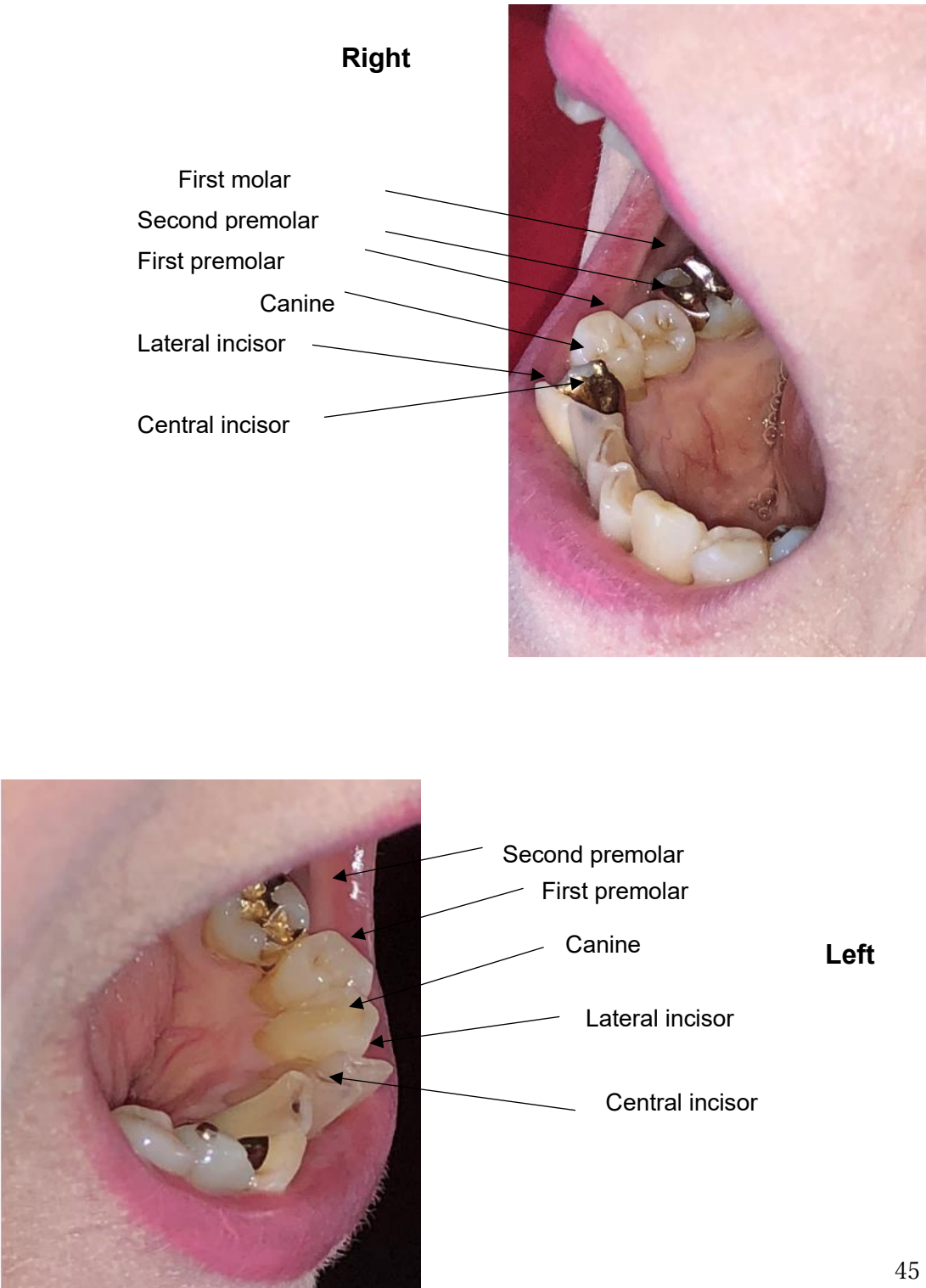
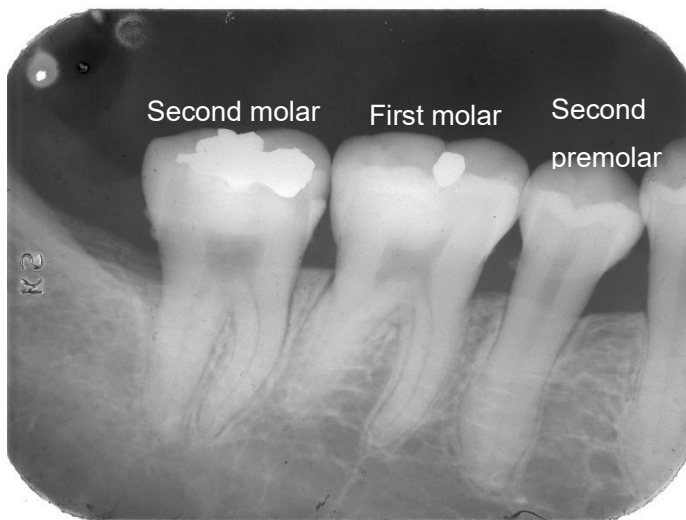


Figure 10. Intra-oral X-ray Images of the Patient's Mandible

Young Adult years (1976~1979)

Right Mandible

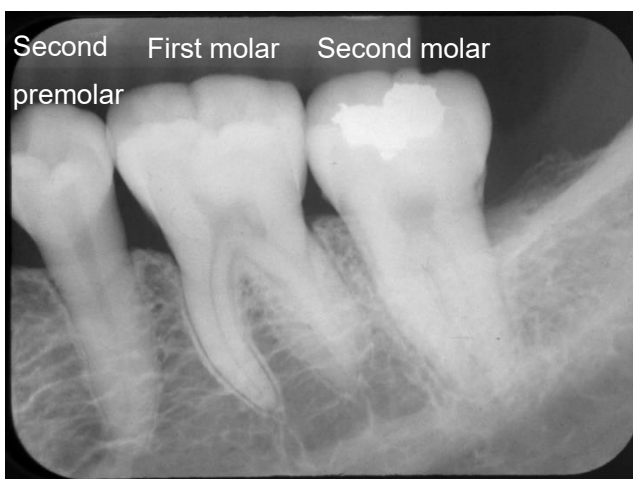
A★★★★



1976.4.9, when she was 36 years old (right m.)
Photo taken for the examination of dental caries

Left Mandible

A★★★★

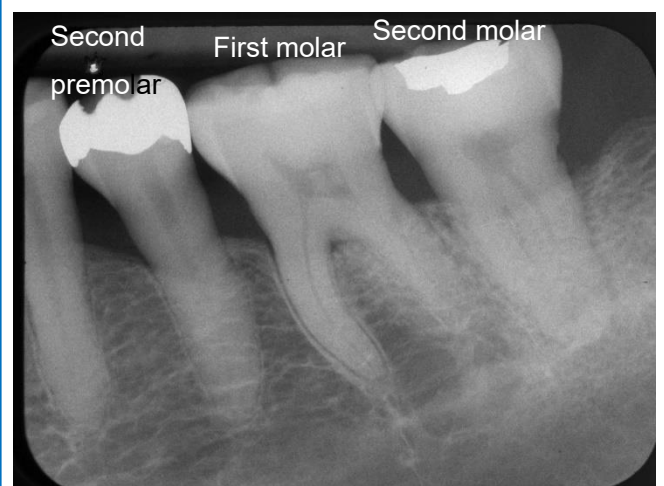


1979.6.30, when she was 39 years old. This left-mandible photo was taken before a dental cleaning was performed.

Photo in 2010, when she was 70 years old.
In the year, the administration of a
bisphosphonate started.

Left Mandible

B



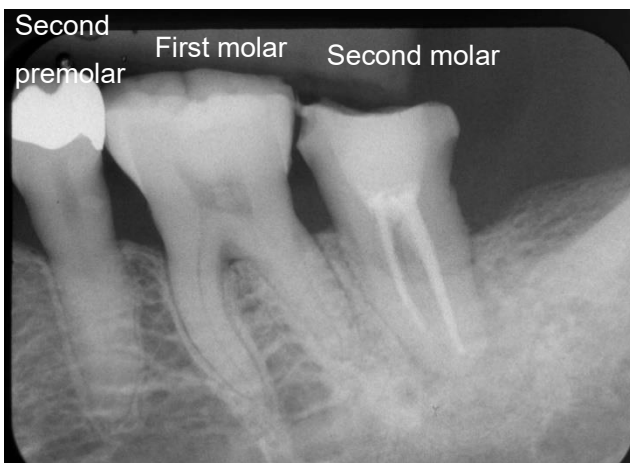
2010.7.23, when she was 70. This left-mandible photo was taken as the patient complained of pain at the left second molar when she chewed food. Crackles were found at its crown part. Its dental pulp necrotized. A root canal treatment was performed.

Photo in 2017, when she was 77.

Seven years after the start of osteoporotic treatment. By this time, she got a total of 6 anti-RANKL monoclonal antibody injections.

Left Mandible

A★

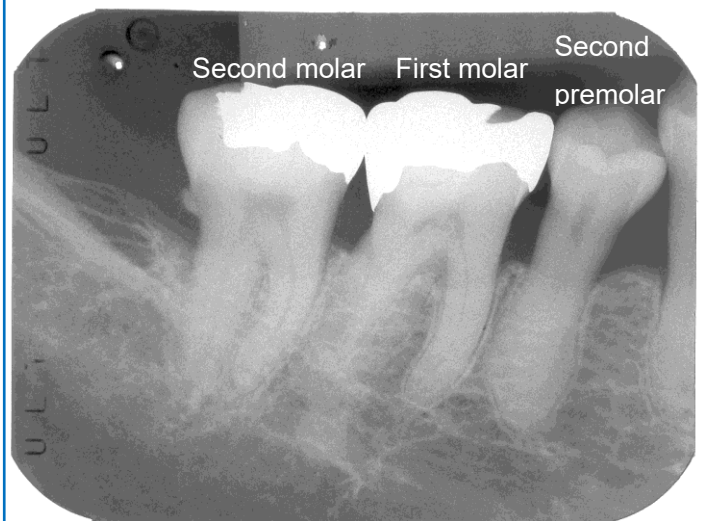


2017.9.9, when she was 77. This X-ray image shows that her trabeculae mesh has become thicker and more conspicuous than that of the 2010 image. The top of her 2nd molar's crown has been replaced with a resin top which does not appear on an X-ray image.

Photo in 2019, when she was 79. Nine years after osteoporosis treatment began. By this time, she got 10 anti-RANKL antibody injections in total.

Right Mandible

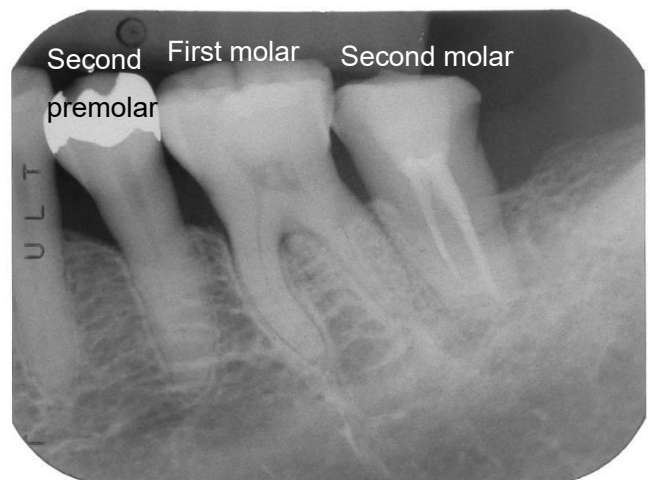
A★★



2019.11.16., when she was 79. Fine trabeculae can be recognized in right-mandible image.

Left Mandible

A★★★



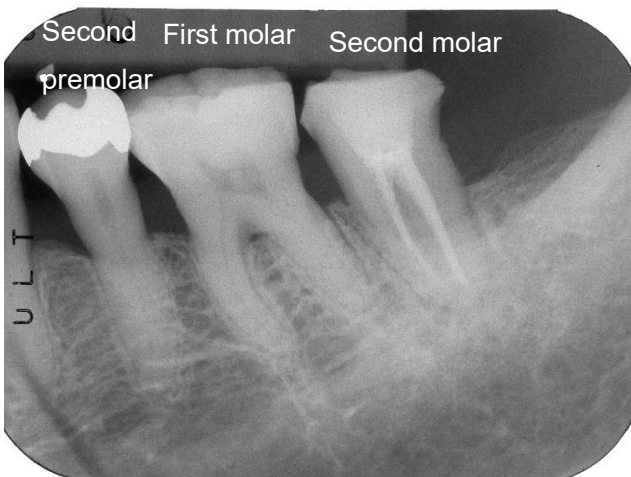
2019.11.16., when she was 79. Here, an even thicker trabeculae mesh is recognized than in the 2017 X-ray image of her left mandible.

Photo in 2021, when she was 81.

Eleven years after the start of osteoporotic treatment. By this time, she got a total of 14 anti-RANKL monoclonal antibody injections.

Left Mandible

A★★★★



2021.7.17, when she was 81. Here, an even finer and thicker trabeculae mesh is seen than in the 2019 X-ray image of her left mandible.



1981-11-10

Patient when she was
41 years old




1986-11-30

Patient when she was 46
years old



2013-06-08

Patient when she was
73 years old

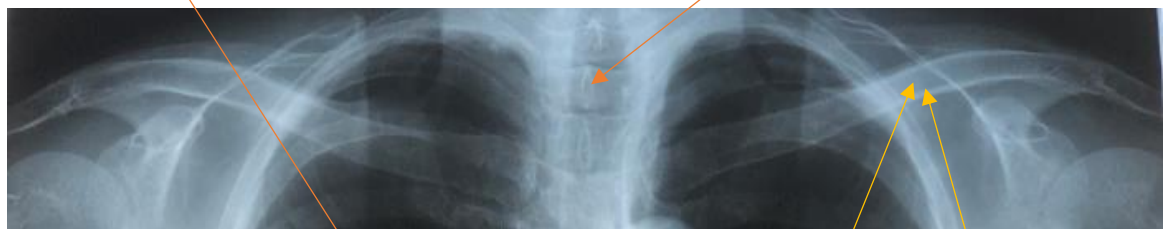

2018 March

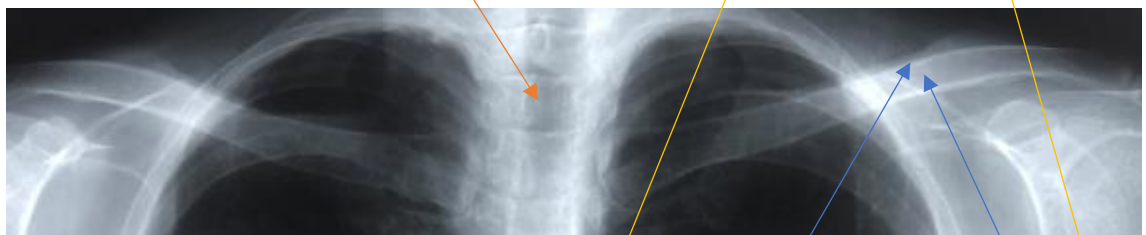
Patient when she
was 78 years old

Figure 11 *Clavicle and cervical vertebrae*: The upper image in Figure 11 shows the patient's chest X-ray image taken at the age of 67 -- three years before the osteoporotic treatment began. The lower image in Figure 11 shows the chest X-ray image at the age of 80 after she received 10 years of osteoporotic treatment. These X-ray images show that the bone mineral density of her clavicle grew much thicker thanks to the osteoporotic treatment, especially with the anti-RANKL monoclonal antibody.

Images of her cervical vertebrae's spongy bones, taken on Oct. 16, 2007 and on Feb. 28, 2020, also show that their bone mineral density became greater after the osteoporotic treatment.

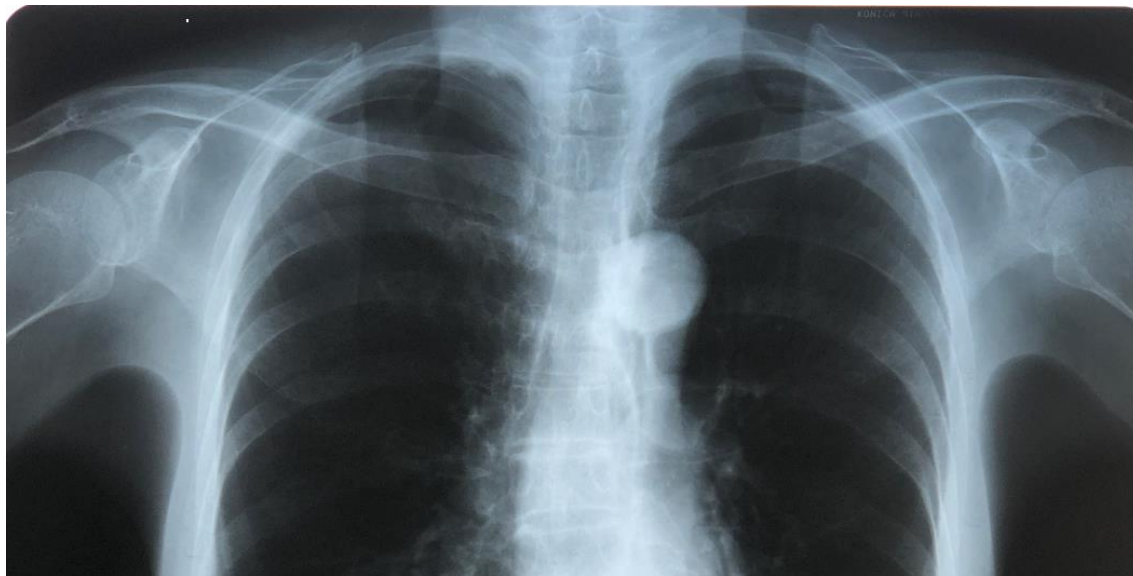


2007.10.16

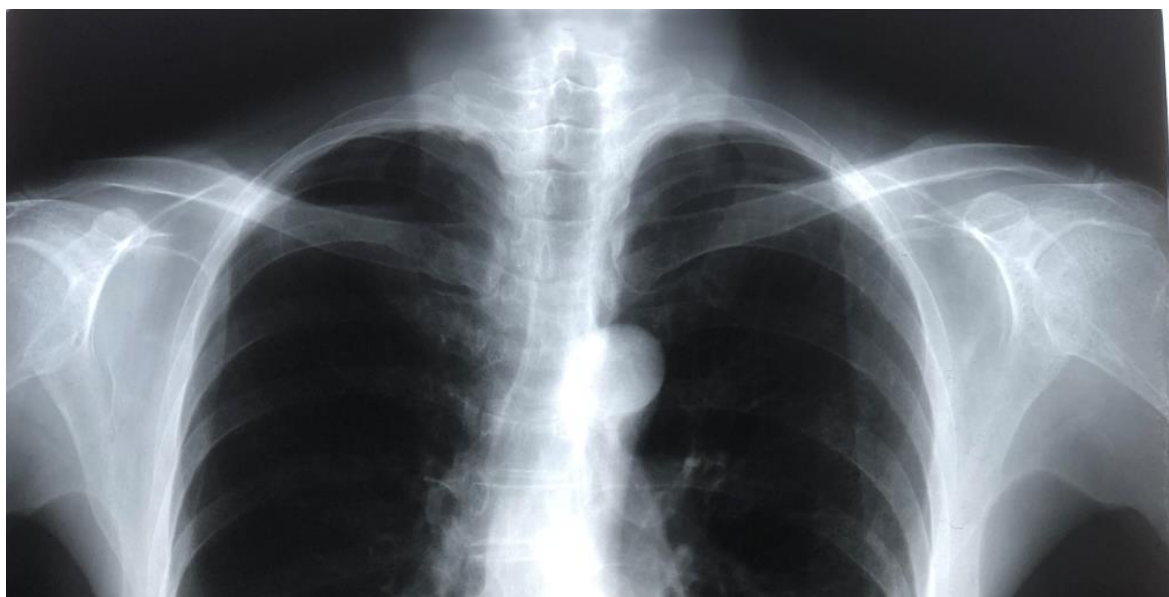


2020.2.28

- (1) Her clavicle's cortex is thicker in the 2020.2.28 X-ray image than in the 2007.10.16 X-ray image.
- (2) The bone mineral density of the clavicle's spongy bone is higher in the 2020.2.28 X-ray image than in the 2007.10.16 X-ray image. This thickening is demonstrated by the fact that the image of the spongy bone is less translucent in the 2020.2.28 X-ray image than in its 2007.10.16 X-ray image.



2007.10.16, when the patient was 67 years old



2020.2.28, when the patient was 80 years old

*The following X-ray images show positive changes in the density of the patient's left tibia and fibula, as well as in her femur's distal end: **Figure 12** in the following page presents X-ray images of her left tibia and fibula taken on three different dates – (1) on January 26, 2009, when she sustained their fractures during a skiing accident (2) on March 15, 2010 -- two months before the start of her osteoporotic treatment with the Alphacalcidol and (3) on August 8, 2019. By the third date, nine years had elapsed since the treatment began. The X-ray image taken on the date shows that the thickness of the cortex of her proximal tibia grew greater than its thickness as of January 26, 2009. We can recognize a similar positive change that occurred at the distal end of her left femur when we compare its X-ray images taken on 2009.1.26 and 2019.8.8.*

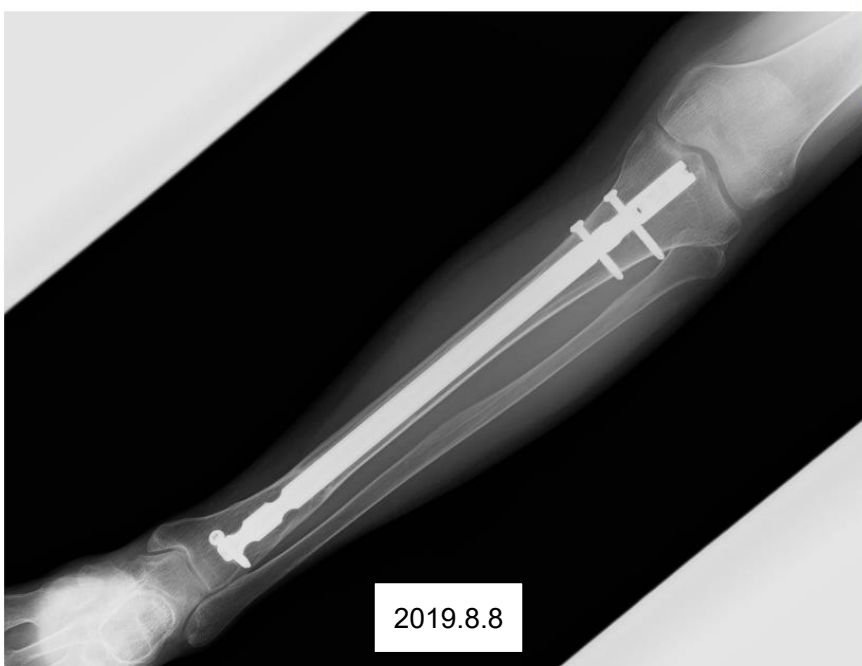
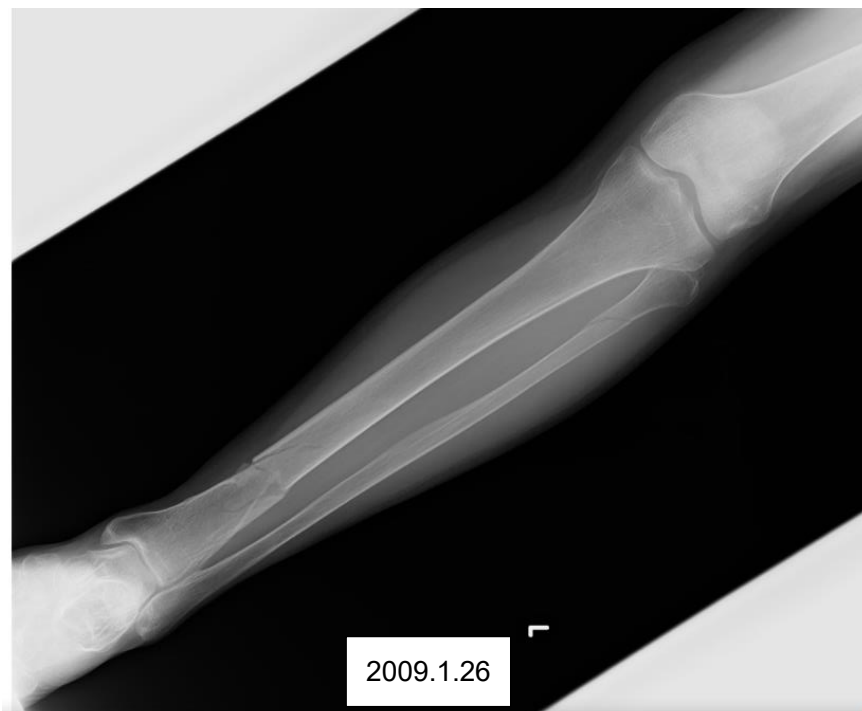
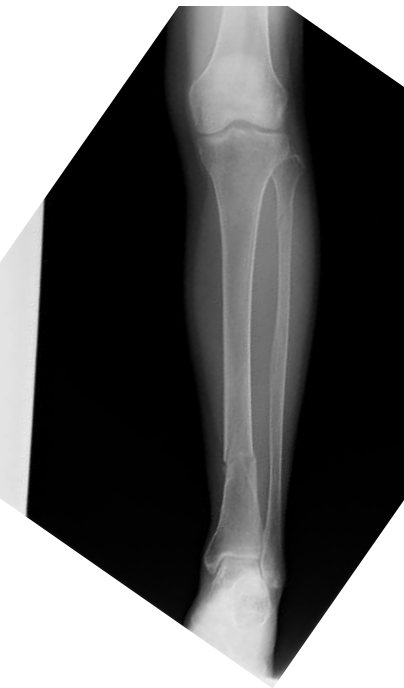
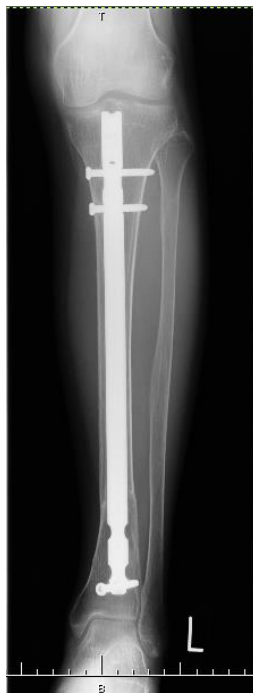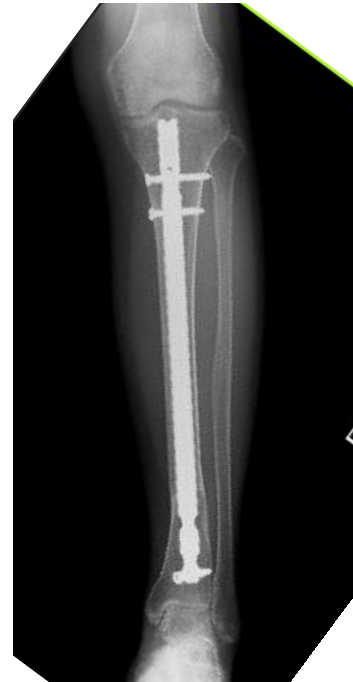Figure 12. X-ray images of positive changes in her left lower extremity



2009.1.26
Day of Fracture



2010.3.15 1 Year and 1
month after the fracture



2019.8.8 Ten years
and 6 months after
the fracture

Table 4. Summary of evaluation of the bone density at the patient's multiple skeletal parts in light of X-ray images, BMD readings and T-scores

	1976~1979 (46-49 years old)	2010~2012 (70~72 years old) Before Teriparatid's daily injections	2015~2017 (75~77 years old) After Teriparatid & anti-RANKL antibody treatment	2019 (79 years old) After 4 years of anti-RANKL antibody injections, which was preceded by 2-year Teriparatid treatment
Right Mandible	A ★★★ 1976.4.9			A ★★ 2019.11.16
Left Mandible	A ★★★ 1979.6.30	B 2010.7.23	A ★ 2017.9.9	A ★★ 2019.11.16
L2~L4 BMD		BMD 0.526 T score -4.6 2012.11.2 72.7 years old	BMD 0.664 26%rise over 2010 T score -3.6 2017.7.14 77.4 years old	BMD 0.706 (This BMD means 34% jump over its 2012 level) T score -3.3 2019.8.8 79.5 years old
Right Femur Neck		BMD 0.462 T score -4.2 2012.11.2 72.7 years old	BMD 0.476 (3% increase) T score -4.1 2015.7.17 75.4 years old	BMD 0.507 (10% increase) T score -3.8 2019.8.8 79.5 years old
Right Femur Proximal Total			BMD 0.480 T score -3.7 2017.1.13 76.9 years old	BMD 0.509 T score -3.5 2019.8.8 79.5 years old
Left Femur Neck		BMD 0.422 T score -4.4 2012.11.2 72.7 years old	BMD 0.453 T score -4.2 (7% increase) 2015.7.17 75.4 years old	BMD 0.506 T score -3.7 (20% increase over the 2012 level) 2019.8.8 79.5 years old
Left Femur Proximal Total			BMD 0.495 T score -3.6 2017.1.13 76.9 years old	BMD 0.545 T score -3.2 2019.8.8 79.5 years old

Table 4 provides a summary of the evaluation of the bone density at the patient's multiple skeletal parts on the basis of the visual examination of their X-ray images and of the analysis of their bone mineral density readings measured with the GE DEXA measuring instruments that produce its measurement results in terms of an **indicator unit of gram per square centimeter (g/cm²)** as well as T-scores computed on the basis of the indicator readings.

The table's second and third columns present the ratings which the patient assigned in light of X-ray images of her left and right mandibular alveolar bones under her four-grade bone mineral density-assessment method. The ratings range from B to A triple stars (in other words, an A+++ , or A triple-plus). The method involves visually examining a mandible's X-ray images and then verifying the appropriateness of the ratings thus assigned, while referring to both BMD and T-score readings measured with the digital multi-slice bone densitometers of General Electric Co.

Mandible: In assessing the thickness and density of her right and left mandibular alveolar bones, authors could count only on the visual examination of intra-oral X-ray images, as the Yokohama dental clinic does not have any multi-slice bone densitometer. But it is with admirably studious care that the clinic has kept track of the state of her mandibular bones for as long as 45 years in light of the X-ray images.

The clinic's observation of her mandibular bone and teeth got under way in 1976, when the patient was 36 years old. Periodic checkups based on X-ray images are still continuing as of August 2021. The rating of A3+ (A triple-plus) was assigned to the X-ray images of both her right and left mandibles, taken during the 1976~1979 period, when the patient was 36-39 years old.

However, in 2010 when she was 70 years old, the rating for the same left mandible plunged as low as B due to a progressing osteoporosis. More than 10 years had passed since she experienced menopause. Two years and five months after she posted the low rating, she started to administer subcutaneous injections of Teriparatid to herself on a daily basis until she discontinued the Teriparatid injections in August 2014 in preparation for the start of the periodic injections of the anti-RANKL monoclonal antibody as directed by Keio University

Hospital. The injection of the monoclonal antibody was conducted at an interval of 6 months. These hypodermic injections are still performed regularly.

By July 16, 2021, her osteoporosis was treated with either the Teriparatid or the anti-RANKL monoclonal antibody for a total of eight years and six months, with the monoclonal antibody-based treatment accounting for a six-year portion of the 8.5-year treatment period. On November 2019, when she was 79 years old, her right and left mandibles were given a high rating of A 2+. Then, on July 17, 2021, her left mandible was given an even higher rating of A3+. By this date, she received a total of 14 anti-RANKL monoclonal body injections. The resultant positive change suggests that the density levels of her right and left mandibular alveolar trabecular bones returned to high levels almost equivalent to the levels which the two parts respectively had in 1976~1979. And the 2021 ratings of A3+ for her left mandible compares with the alarming B rating assigned to the same site on July 23, 2010.

Clavicle:

In assessing the thickness and density of her clavicle, authors could count only on her chest X-ray images, which were taken at the Sakai Clinic in Kawasaki City, Kanagawa Prefecture, where she has had her chest roentgenized from time to time.

The close comparison of two chest X-ray images -- taken on October 16, 2007, and then on February 28, 2020 -- showed that the bone mineral density of her clavicle's spongy bone grew thicker and greater thanks to the eight-years-and-six-months osteoporotic treatment based on the Teriparatid and the anti-RANKL monoclonal antibody. During the initial 20 months of the 8.5-year period, the Teriparatid was administered to the patient until Keio University Hospital switched to the anti-RANKL monoclonal antibody-based treatment strategy on January 16, 2015. The new strategy has been followed over the past six years and six months until the present day (September 4, 2021).

Vertebrae: The bone mineral density readings at the patient's L2~L4 have been measured with the DEXA instruments since November 2, 2012, when the patient was 72 years old. She has gotten the Keio University Hospital to

examine and check the bone mineral density at the L2~4 and at other skeletal parts until today. A jump in the L2~4's bone mineral density readings was attained especially after the 2015 start of the administration of the anti-RANKL monoclonal antibody.

The bone mineral density readings at the L2~L4 stood at a meager 0.526 g/cm² on November 2, 2012, before the corresponding reading shot up to 0.706 g/cm² on August 8, 2019. The change signifies a **34 percent upsurge** over the L2~L4 BMD reading of November 2, 2012.

When we compared the chest X-ray images taken on October 16, 2007, and on February 28, 2020, we could confirm that the thickness of her cervical vertebrae became greater after the osteoporosis treatment was performed. We recognized the occurrence of a clear increase in the bone mineral density of cervical vertebrae after her osteoporosis was treated first with the Teriparatid and then with the anti-RANKL monoclonal antibody.

Tibia: As in the cases of the mandible and clavicle, only X-ray images were available to enable us to conduct the evaluation of the degrees of her tibia's bone mineral density. But a long temporal series of the X-ray images of her tibia clearly showed that the cortex of her proximal tibia became thicker after the treatment of her osteoporosis with the Teriparatid and the anti-RANKL monoclonal antibody.

Femur: Bone mineral density at the patient's right and left femur necks have been monitored and measured with the DEXA multi-slice densitometer since November 2, 2012.

BMD reading at her left femur neck stood at a disappointing 0.422 g/cm² on November 2, 2012. But the corresponding reading at the same site bounced back to 0.506 g/cm² on August 8, 2019. The rebound represented a 20 percent leap at the site's bone mineral density of November 2, 2012. Meanwhile, the BMD reading at her right femur neck bounced back to 0.507 g/cm² on August 8, 2019, against the corresponding reading of 0.462 g/cm² of November 2, 2012. The change signifies a 10% rise at the site's bone mineral density. These positive changes should be attributed especially to the osteoporotic treatment with the

anti-RANKL monoclonal antibody.

The X-ray images of the distal part of the patient's left femur – taken on January 26, 2009, and August 8, 2019 -- showed that the bone mineral density of the part's cortex became thicker in the wake of her osteoporotic treatment. The authors had to rely on visual checkups of X-ray images when we tried to assess changes in the density of her left tibia and fibula as BMD readings and T-score readings were not available for the parts. But the X-ray images of various lower extremity skeletal parts showed their improvements after years of osteoporotic treatment with the Teripatide and the anti-RANKL monoclonal antibody.

DISCUSSION

Table 5 classifies bones in accordance with morphological features of the bones, while providing information on which ossification mechanism -- out of an intramembranous ossification mechanism or an endochondral ossification mechanism -- forms these bones.

Bones analyzed in this paper fall into two main groups. The first group consists of plane and irregular bones, which are formed through the intramembranous ossification mechanism. The other group comprises long bones, which are formed through the endochondral ossification mechanism. (Table 5)

Table 5. Bone Classification and Ossification Mechanism for bone types

	Classification	Ossification Mechanism
Mandible	Plane bone	Intramembranous Ossification
Clavicle	Plane bone	Intramembranous Ossification
Vertebrae	Irregular bone	Intramembranous Ossification
Femur	Long bone	Endochondral ossification
Tibia	Long bone	Endochondral ossification
Fibula	Long bone	Endochondral ossification

1. Intramembranous Ossification (involved in the development of Flat Bones of Skull, Mandible and Clavicle, Vertebrae)

In cases where an intramembranous ossification mechanism functions, a group of mesenchymal cells within a highly vascularized area of the embryonic connective tissue proliferates and differentiates directly into osteoblast precursors before differentiating into osteoblasts. These cells synthesize and secrete osteoid which is calcified to become woven bones. Blood vessels incorporated between the woven bone trabeculae subsequently form a hematopoietic bone marrow.

Later, the woven bone is remodeled and is progressively replaced by mature lamellar bone. In the early stage of a human's fetal life, resorption and apposition begin to take place so that the cancellous bone (also called trabecular, or spongy bone) may occupy the center of the mass, while a layer of cortical bone is formed on each side of the cancellous bone through a continuous addition of new sheets of bone by active osteoblasts. Osteoclasts resorb bone from the inner surface to maintain a balanced thickness and shape of the bone.

2. Endochondral ossification (Femur, Tibia, Fibula, Humerus, Radius, Ulna)

In an endochondral ossification, an epiphyseal cartilage is involved during the ossification process at which osseous tissue is formed by the replacement of calcified cartilage. The endochondral ossification is an essential process during the rudimentary formation of long bones, which is formed by way of the extension of the length of long bones at the epiphyseal plate, where osteoblasts form bone trabeculae on a framework of calcified cartilage.

On the basis of our observation, we set up a hypothesis that a treatment of osteoporosis on the basis of a successive administration of the Teriparatid and the anti-RANKL monoclonal antibody tends to be more effective for the category of bones which are formed via an intramembranous ossification mechanism than for those formed via an endochondral ossification mechanism. Among various types of skeletal parts, the treatment with the successive use of the Teriparatide and the anti-RANKL monoclonal antibody proved to be most effective for mandibles.

The fineness and minuteness of the patient's left mandibular alveolar bone's trabecular bone mesh, which plummeted to the B ranking in 2010 after she experienced menopause, dramatically bounced back to the A triple-plus ranking on July 17, 2021, after eleven years of osteoporotic treatments, with the trabecular meshwork's fineness reaching the high level almost equivalent to the level which the left mandible had when the patient was 39 years old.

CONCLUSION

A relation between teeth and a mandibular trabecular bone can be compared to a relation between a building and its foundation stones. The well-being of teeth depends upon the sound condition and the robustness of the mandibular trabecular bones to a great extent.

A breakout of an osteoporosis at the trabecular bones of a person's mandibular alveolar bones as well as its aggravation carry the risk of widening a sulcus between a tooth and gingiva. Such an enlarged sulcus tends to act as a portal of entry for bacteria of an oral flora. This might induce a periodontitis.

A periodontitis would trigger a reduction in the quantity of mandibular and maxillary bones, just as an osteoporosis does. Just as a building would crumble in cases where its foundation stones break, teeth would not be able to stay in their proper positions in an oral cavity and their quality would deteriorate if a periodontitis combined with a serious osteoporosis at the mandibular alveolar bone.

Maintaining the health of teeth is a prerequisite to enable humans to enjoy an active and comfortable life. Therefore, it is very important to prevent osteoporosis from undercutting the quality of the mandible and maxilla.

Our examination of the 45-year mandibular bone observation results at this 81-year-old female and the excellent improvements at her mandible's density as a windfall consequence of her osteoporotic treatment suggests that the most up-to-date treatment with the anti-RANKL monoclonal antibody was so effective that her mandibular bones' mineral density returned to a high level almost equivalent to the level which her mandible had when she was in her thirties.

The author and co-authors do not have any conflict of interest to disclose regarding this academic paper.

REFERENCES

1. Niki M. Moutsopolous, Joanne E.Konkel. Tissue-Specific Immunity at the Oral Mucosal Barrier. Trends in Immunology 39(4):276-287, 2018
2. Grethe Jonasson, Annika Billhult. Mandibular bone structure, bone mineral density, and clinical variables as fracture predictors: a 15-year follow-up of female patients in a dental clinic. 116(3):362-368, 2013
3. Jonasson G, Jonasson L, Kiliaridis S. Skeletal bone mineral density in relation to thickness, bone mass, and structure of the mandibular alveolar process in dentate men and women. Eur J Oral Sci 115:117-123, 2007
4. Diagnostic criteria of Primary Osteoporosis (2012 revised version). Osteoporosis Japan 21(1):9-21, 2013, the Japanese Society of Bone and Mineral Research (JSBMR)
5. Diagnostic criteria of Primary Osteoporosis (1996 revised version). Osteoporosis Japan 14(4):219-233, 1997, JSBMR
6. Diagnostic Criteria of Primary Osteoporosis (2000 revised version). JSBMR Osteoporosis Japan (0910-0067)18(3):76-82, 2000
7. Harumi Kuno-Sakai, Mutsuo Fukushima, Hiroyuki Sakai, Takeshi Miyamoto, Taito Itabashi, Hideto Sakai. Efficaciousness of Postmenopausal Osteoporosis Treatment with the Mix of active Vitamin D3 agents, a Bisphosphonate (risedronate), a Teriparatide, and the Monoclonal Antibody against RANKL: A 10-year follow-up report on a female patient. International Journal of Geriatrics and Rehabilitation 2(1):1-68, 2020

APPENDIX

Table 6. Bone Mineral Density L2-L4L2-L4: Young Adult (Female, Age Range: 20-44 old), BMD-YAM \pm 1 SD 1.192 \pm 0.146 g/cm²

Date	Patient Age (Year)	L2-L4	Patient/YAM	T score: (Patient-YAM)/0.146	Age specific BMD (g/cm ²)	Age specific BMD Mean+1 SD	Age specific BMD Mean-1 SD	Patient/ Age specific Mean	Z score: (Patient-Age specific Mean)/0.146
2012/11/2	72.7	0.526	44%	-4.6	0.841	0.987	0.695	63%	-2.2
2013/2/1	73.0	0.526	44%	-4.6	0.839	0.985	0.693	63%	-2.1
2013/6/28	73.4	0.563	47%	-4.3	0.837	0.983	0.691	67%	-1.9
2013/12/27	73.9	0.595	50%	-4.1	0.833	0.979	0.687	71%	-1.6
2015/1/16	74.9	0.581	49%	-4.2	0.827	0.973	0.681	70%	-1.7
2015/7/17	75.4	0.643	54%	-3.8	0.823	0.969	0.677	78%	-1.2
2017/1/13	76.9	0.672	56%	-3.6	0.813	0.959	0.667	83%	-1.0
2017/7/14	77.4	0.664	56%	-3.6	0.810	0.956	0.664	82%	-1.0
2018/1/12	77.9	0.677	57%	-3.5	0.807	0.953	0.661	84%	-0.9
2019/1/11	78.9	0.694	58%	-3.4	0.800	0.946	0.654	87%	-0.7
2019/8/8	79.5	0.706	59%	-3.3	0.796	0.942	0.650	89%	-0.6
2020/1/17	80.0	0.627	53%	-3.9	0.794	0.940	0.648	79%	-1.1
2021/1/15	80.9	0.668	56%	-3.6	0.787	0.933	0.641	85%	-0.8

Table 7. Right Femur NeckRight Femur Neck: Young Adult (Female, Age Range: 20-29 old), BMD: YAM \pm 1 SD 0.939 \pm 0.114 g/cm²

Date	Patient Age (Year)	Right Femur Neck	Patient/ YAM	T score: (Patient-YAM)/ 0.114	Age specific BMD (g/cm ²)	Age specific BMD Mean+ 1 SD	Age specific BMD Mean- 1 SD	Patient/ Age specific Mean	Z score: (Patient-Age specific Mean)/ 0.114
2012/11/2	72.7	0.462	49%	-4.2	0.675	0.789	0.561	68%	-1.8
2013/2/1	73.0	0.455	48%	-4.2	0.673	0.787	0.559	68%	-1.9
2013/6/28	73.4	0.467	50%	-4.1	0.670	0.784	0.556	70%	-1.8
2013/12/27	73.9	0.459	49%	-4.2	0.666	0.780	0.552	69%	-1.8
2015/1/16	74.9	0.469	50%	-4.1	0.658	0.772	0.544	71%	-1.7
2015/7/17	75.4	0.476	51%	-4.1	0.655	0.769	0.541	73%	-1.6
2017/1/13	76.9				0.643	0.757	0.529		
2017/7/14	77.4				0.640	0.754	0.526		
2018/1/12	77.9				0.636	0.750	0.522		
2019/1/11	78.9				0.628	0.742	0.514		
2019/8/8	79.5	0.507	54%	-3.8	0.624	0.738	0.510	81%	-1.0
2020/1/17	80.0								
2021/1/15	80.9								

Table 8. Left Femur NeckLeft Femur Neck: Young Adult (Female, Age Range: 20-29 old), BMD: YAM \pm 1 SD 0.939 \pm 0.114 g/cm²

Date	Patient Age (Year)	Left Femur Neck	Patient/ YAM	T score: (Patient-YAM)/ 0.114	Age specific BMD (g/cm ²)	Age specific BMD Mean+ 1 SD	Age specific BMD Mean- 1 SD	Patient/ Age specific Mean	Z score: (Patient-Age specific Mean)/ 0.114
2012/11/2	72.7	0.422	45%	-4.4	0.675	0.789	0.561	63%	-2.2
2013/2/1	73.0	0.450	48%	-4.2	0.673	0.787	0.559	67%	-2.0
2013/6/28	73.4	0.449	48%	-4.2	0.670	0.784	0.556	67%	-1.9
2013/12/27	73.9	0.452	48%	-4.2	0.666	0.780	0.552	68%	-1.9
2015/1/16	74.9	0.453	48%	-4.2	0.658	0.772	0.544	69%	-1.8
2015/7/17	75.4	0.453	48%	-4.2	0.655	0.769	0.541	69%	-1.8
2017/1/13	76.9				0.643	0.757	0.529		
2017/7/14	77.4				0.640	0.754	0.526		
2018/1/12	77.9				0.636	0.750	0.522		
2019/1/11	78.9				0.628	0.742	0.514		
2019/8/8	79.5	0.506	54%	-3.7	0.624	0.738	0.510	81%	-1.0
2020/1/17	80.0								
2021/1/15	80.9								

Table 9. Right Femur Proximal TotalRight Femur Proximal Total: Young Adult (Female, Age Range: 20-29 old), BMD: YAM \pm 1 SD 0.961 \pm 0.130 g/cm²

Date	Patient Age (Year)	Right Femur Proximal Total	Patient/ YAM	T score: (Patient-YAM)/ 0.130	Age specific BMD (g/cm ²)	Age specific BMD Mean+ 1 SD	Age specific BMD Mean- 1 SD	Patient/ Age specific Mean	Z score: (Patient-Age specific Mean)/ 0.130
2012/11/2	72.7				0.714	0.844	0.584		
2013/2/1	73.0				0.712	0.842	0.582		
2013/6/28	73.4				0.709	0.839	0.579		
2013/12/27	73.9				0.705	0.835	0.575		
2015/1/16	74.9				0.697	0.827	0.567		
2015/7/17	75.4				0.693	0.823	0.563		
2017/1/13	76.9	0.480	50%	-3.7	0.682	0.812	0.552	70%	-1.6
2017/7/14	77.4	0.492	51%	-3.6	0.678	0.808	0.548	73%	-1.4
2018/1/12	77.9	0.479	50%	-3.7	0.674	0.804	0.544	71%	-1.5
2019/1/11	78.9	0.506	53%	-3.5	0.666	0.796	0.536	76%	-1.2
2019/8/8	79.5	0.509	53%	-3.5	0.662	0.792	0.532	77%	-1.2
2020/1/17	80.0	0.490	51%	-3.6	0.658	0.788	0.528	74%	-1.3
2021/1/15	80.9	0.488	51%	-3.6	0.651	0.781	0.521	75%	-1.3

Table 10. Left Femur Proximal TotalLeft Femur Proximal Total: Young Adult (Female, Age Range: 20-29 old), BMD: YAM \pm 1 SD 0.961 \pm 0.130 g/cm²

Date	Patient Age (Year)	Left Femur Proximal Total	Patient/ YAM	T score: (Patient-YAM)/ 0.130	Age specific BMD (g/cm ²)	Age specific BMD Mean+ 1 SD	Age specific BMD Mean- 1 SD	Patient/ Age specific Mean	Z score: (Patient-Age specific Mean)/ 0.130
2012/11/2	72.7				0.714	0.844	0.584		
2013/2/1	73.0				0.712	0.842	0.582		
2013/6/28	73.4				0.709	0.839	0.579		
2013/12/27	73.9				0.705	0.835	0.575		
2015/1/16	74.9				0.697	0.827	0.567		
2015/7/17	75.4				0.693	0.823	0.563		
2017/1/13	76.9	0.495	52%	-3.6	0.682	0.812	0.552	73%	-1.4
2017/7/14	77.4	0.526	55%	-3.3	0.678	0.808	0.548	78%	-1.2
2018/1/12	77.9	0.522	54%	-3.4	0.674	0.804	0.544	77%	-1.2
2019/1/11	78.9	0.531	55%	-3.3	0.666	0.796	0.536	80%	-1.0
2019/8/8	79.5	0.545	57%	-3.2	0.662	0.792	0.532	82%	-0.9
2020/1/17	80.0	0.517	54%	-3.4	0.658	0.788	0.528	79%	-1.1
2021/1/15	80.9	0.528	55%	-3.3	0.651	0.781	0.521	81%	-0.9